International Journal of Chemical Studies

P-ISSN: 2349–8528
E-ISSN: 2321–4902
www.chemijournal.com
IJCS 2023; 11(1): 51-54

Received: 06-10-2022
Accepted: 11-12-2022

Madhu D
Ph. D scholar, Department of Veterinary Anatomy and Histology, Veterinary College, Hebbal, Bangalore, Karnataka, India

Prasad RV
Retired Professor, Department of Veterinary Anatomy and Histology, Veterinary College, Hebbal, Bangalore, Karnataka, India

Jamuna KV
Retired Professor, Department of Veterinary Anatomy and Histology, Veterinary College, Hebbal, Bangalore, Karnataka, India

Sathyanarayan K
President, Karnataka Veterinary Council, Veterinary College, Hebbal, Bangalore, Karnataka, India

Nagaraj CS
Dean, Veterinary College, Hebbal, Bangalore, Karnataka, India

Shridhar NB
Professor and Head, Department of Veterinary Pharmacology, Veterinary College, Shivamogga, Karnataka, India

Corresponding Author:
Madhu D
Ph. D scholar, Department of Veterinary Anatomy and Histology, Veterinary College, Hebbal, Bangalore, Karnataka, India

Histological structure of liver in nilgai (*Boselaphus tragocamelus*)

Madhu D, Prasad RV, Jamuna KV, Sathyanarayan K, Nagaraj CS and Shridhar NB

Abstract
The present study was carried out on the liver of four nilgai collected from Chamarajendra Zoological Garden, Mysore. Histologically, the liver was surrounded by Glisson's capsule, composed mainly of collagen with few smooth muscle fibers. The hepatocytes radiated from the central vein towards the portal triad. Fine meshwork of reticular fibres were surrounding the hepatocytes, central and portal vein. Histochemically the capsule showed weak PAS reaction. However, the hepatocytes were moderately PAS positive towards the portal triad. At places in between the hepatocytes in the sinusoidal space few cells showed moderate to strong PAS character in their cytoplasm.

Keywords: Liver, nilgai, Glisson's capsule, hepatocytes, portal triad

Introduction
Nilgai (*Boselaphus tragocamelus*) is a member of bovidae family commonly called blue bull and is considered to be Asia's largest antelope. Nilgai's are most common in the northern India and it is a menace animal as it destroys the agricultural crops. These nilgai's are in close association with domestic animals as it is in vicinity with human territory. Nilgai is a wild ruminant and they are always prune for diseases and can intern transmit the disease to the domestic animals.

To understand the pathology of vital organs, it is essential to understand the histology of these wild animals. Liver is the largest gland in the body which functions in excretion of waste products, storage (lipids, vitamins and glycogen), secretion (bile), phagocytosis, detoxification, synthesis of albumin and globulin, metabolism of carbohydrates, lipids, drugs and also hemopoiesis in embryonic stages, so understanding the structure of the liver is important to study these processes.

Until now, no such information has been presented on the liver histology of nilgai in the literature reviewed. Therefore to understand the histomorphology and carbohydrate histochemistry the study was conducted on nilgai liver.

Material and Methods
Four nilgai liver samples were collected from the Chamaraja Zoological Garden, Mysore during post mortem examination, the permission for the collection of nilgai liver sample was taken from Principal Chief Conservator of Forest (Wild Life) Government of Karnataka. The samples from the nilgai are collected from the animals which are die due to in fighting and were fixed in 10% Neutral buffered formaline as soon as possible. The samples were processed by routine ethanol - chloroform sequence and embedded in paraffin. Sections were cut at 6 µm thickness and were utilized for histological and histochemical studies. Various staining methods like Mayer's haemalum-eosin- phloxine method (Singh and Sulochana, 1996) [14], Van Gieson's stain (Culling, 1974) [4], Verhoeff's stain (Singh and Sulochana, 1996) [14], Gomori's method (Luna, 1968) [8], Masson's trichrome (Singh and Sulochana, 1996) [14] and Periodic Acid Schiff's reaction (Culling, 1974) [4] were adopted to study the histology and histochemistry of nilgai liver.

Results and Discussion
Histologically the capsule was fibromuscular and was characterized by rows of muscular arteries and predominance of collagen fibres over elastic and smooth muscle fibres (Fig 1)

which were comparable with the findings in goat (Modekar *et al.*, 2003) [12] and tiger (Mehta *et al.*, 2007) [10]. Aziz (1984) [1] reported the absence of smooth muscle fibres and elastic fibres in the capsule of sheep liver. Carollo *et al.* (2012) [3] showed that in the hepatic capsule of cattle, goat and reindeer livers, the connective tissue was present in small quantities.

The hepatocytes radiated from the central vein towards the periphery of the ill-defined hepatic lobule with spar city of connective tissue. Anastamosis of hepatic laminae were discerned towards the periphery of the lobule (Fig 2). Six to eight sided hepatocytes were distributed in the parenchymas (Fig 3) which were similar to the description given by Banks (1993) [2] in domestic animals. The vesicular round nucleus contained predominant nucleoli and uniformly distributed clumps of heterochromatin. Binucleated cells were a feature of few hepatocytes (Fig 3) which were also seen in the text described by Banks (1993) [2] in domestic animals. However, such features were not common in bison liver (Prunescu *et al*., 2002) [13].

The hepatic sinusoids were lined by spindle shaped endothelial cells and stellate shaped macrophages (Kupffer cells) (Fig 4) similar observation was described by Dhoolappa (2002) [5] in donkey. Large number of erythrocytes and leucocytes were seen in the sinusoids. The perisinusoidal space of Disse was well defined between hepatocytes and sinusoidal lining.

The portal triad consisted of portal vein, hepatic artery and the bile duct (Fig 5) similar to the observations made by Dhoolappa (2002) [5] in donkey, Mehta *et al.* (2007) [10] in tiger, Banks (1993) [2] and Eurell and Frappier (2006) [6] in domestic animals.

The canal of Herring opened into the main duct of the portal area which was lined by simple cuboidal epithelium (Fig 6). The lumen of bile duct showed the presence of secretory material. The portal vein was lined by simple endothelial cells with connective tissue present all around. The lumen was occupied by blood leucocytes, erythrocytes and haemolysed RBC's. Eurell and Frappier (2006) [6] reported that the bile canaliculi were minute canals between opposed hepatocytes.

The reticular fibres were evident as branched strands around hepatocyte as well as in the lining of sinusoidal space (Fig 7). They formed fine meshwork around the central vein, portal vein, hepatic artery as well as around the bile duct. Reported the network of reticular fibres between the sinusoidal lining and the hepatic cells in the liver parenchyma of camel. Mehta *et al.* (2007) [10] reported that the reticular fibres were abundant around the portal area, ducts, and blood vessels and also in the parenchyma of tiger liver. Elastic fibres were not appreciated in the hepatic parenchyma except for stray fibres around the central vein.

Histochemically the capsule of the liver showed weak PAS positive reaction (Fig 8) whereas Dhoolappa (2002) [5] reported strong PAS positive reaction in the capsule of donkey liver. The interlobular connective tissue also showed very weak PAS Positive character towards the portal triad. In the portal triad PAS positive reaction was very weak however; the hepatocytes were moderately PAS positive towards the portal triad (Fig 9). Miraglia *et al.* (1975) [11] observed strong PAS reaction throughout the liver parenchyma in the marmoset liver, whereas in sheep the hepatocytes towards periportal region demonstrated strong PAS reaction than at the centrilobular region (Aziz, 1984) [1].

The central vein did not show any PAS positive reaction. At places in between the hepatocytes in the sinusoidal space few cells showed moderate to strong PAS positive reaction in their cytoplasm (Fig 10).

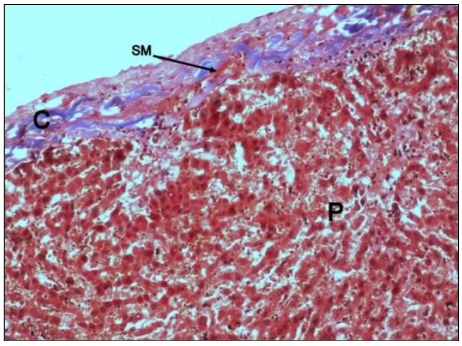

Fig 1: Photomicrograph showing fibromuscular nature of capsule in nilgai liver. C- capsule, SM- smooth muscle, P- parenchyma. Masson's trichrome X100

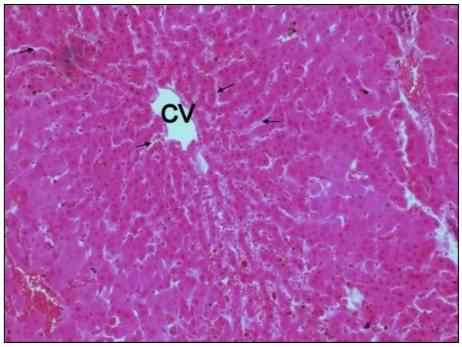

Fig 2: Photomicrograph showing liver sinusoids and radiating arrangement of hepatocytes from the central vein in nilgai. CV- central vein, the arrows indicating the sinusoid. H&E X400

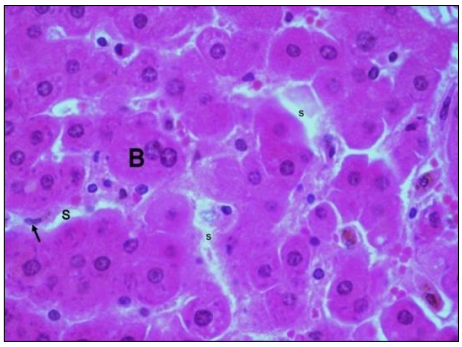

Fig 3: Photomicrograph showing liver sinusoids and the binucleated hepatocytes in nilgai liver. B- binucleated hepatocyte, S- sinusoid. H&E X400

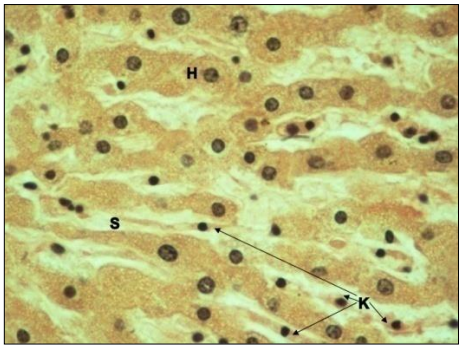

Fig 4: Photomicrograph showing liver sinusoids and the kupffer cells in nilgai liver. H- Hepatocyte, S- sinusoid, K – kupffer cell. Van Giesons X400

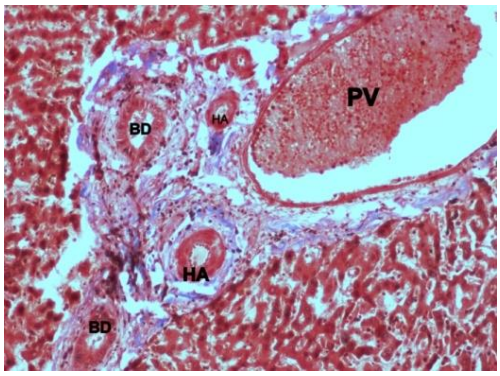

Fig 5: Photomicrograph showing portal triad covered by thick collagen fibre in the liver of nilgai. PV- portal vein, BD- bile duct, HA- hepatic artery. Masson's trichrome X100

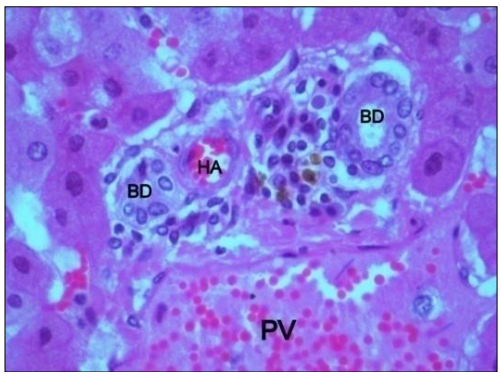

Fig 6: Photomicrograph showing portal triad, the portal vein presents many RBC's in the liver of nilgai. PV- portal vein, BD- bile duct, HA- hepatic artery. H&E X400

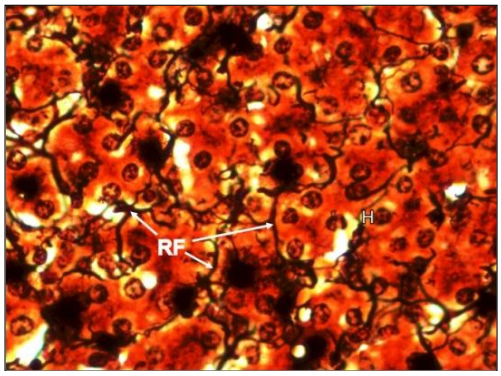

Fig 7: Photomicrograph showing reticular fibres in the liver parenchyma of nilgai. RF- reticular fibre, H- hepatocyte. Gomori's method X400

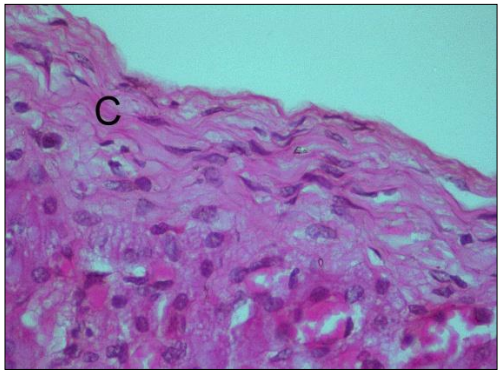

Fig 8: Photomicrograph showing weak PAS positive reaction of the capsule in nilgai liver. C- capsule. PAS X400

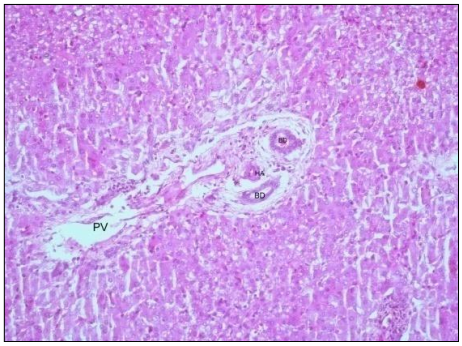

Fig 9: Photomicrograph showing weak reaction PAS reaction in the portal triad in the liver of nilgai. HA- hepatic artery, BD- bile duct, PV- portal vein. PAS X400

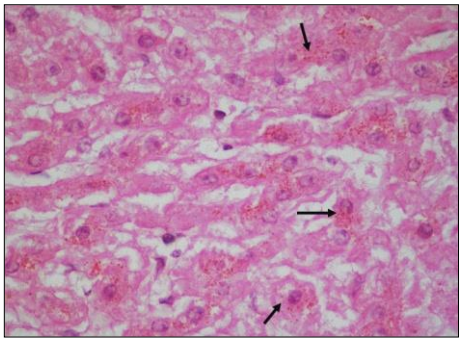

Fig 10: Photomicrograph showing PAS + ve granules in the cytoplasm of hepatocytes in the nilgai. The arrows showing granules in the cytoplasm of the hepatocytes. PAS X400

Conclusion

Understanding the anatomy and pathophysiology of nilgai's liver is important as these animal can transmit the disease to domestic animals. This study provides basic anatomical feature of nilgai liver which can be referred in future research.

Acknowledgement

1. Shri Chamarajendra Zoological Gardens, Mysore, Karnataka.
2. Principal Chief Conservator of Forest (Wild Life) Government of Karnataka, Aranya Bhavana, II floor, 18th cross, Malleshwaram, Bangalore- 560003

References

1. Aziz SH. Gross, histomorphological and histochemical studies on liver of sheep. M. V. Sc. thesis, Punjab Agricultural University, Ludhiana, India. 1984.
2. Banks WJ. Applied Veterinary Histology, Edn. 3rd Mosby year book, St. Louis Baltimore. 1993, 360-373.
3. Carollo V, Giancamillo AD, Vitari F, Schneider R, Domeneghini C. Immunohistochemical aspects of Ito and Kupffer cells in the liver of domesticated and wild ruminants. Open. J Vet. Med. 2012;2:129-136.
4. Culling CFA. Handbook of Histopathological and Histochemical Techniques. Edn. 3rd. Butterworth and Co. Ltd., London, 1974, 219-268.
5. Dhoolappa M. Macro and micro anatomy of liver and pancreas in Indian donkey (*Equus asinus*). M.V.Sc. thesis, University of Agricultural Sciences, Dharwad, Karnataka, India, 2002.
6. Eurell JA, Frappier BL. Dellmanns Text Book of Veterinary Histology., 6th edition, Black well publishing, 2006, 147-232.

7. Huaitao C, Wenhui W, Xiaoming L, Xuanren. Studies on morphostructure of liver in bactrian camel. Acta. Vet. Zootech. Sin. 1996;27(6):539-545.
8. Luna LG. Manual of Histological Staining Methods, of Armed Forces Institute of Pathology. 3rd edn. McGraw Hill book Co., New York, 1968.
9. Mahato T, Dhara K, Roy S. Studies on gross anatomical and histological architecture of the liver of spotted deer. In Proceedings of Souvenier & Abstracts XIX Convension of IAVA & National Symposium, 2004, 18.
10. Mehta S, Amal B, Kallol G. Histopathological studies on liver and gall bladder of tiger: A case report. Indian. J Vet. Anat. 2007;19(2):71-72.
11. Miraglia T, Siqueira LA, Gorini D, Pinto G. Histochemical data on the liver of the marmoset (*Callithrix jacchus*). Acta. Anat. 1975;91:57-70.
12. Modekar SS, Bhosle NS, Mamde CS, Gaikwad SA. Histology of the liver in Osmanabadi breed of goat (*Capra hircus*). J Bombay. Vet. College. 2003;11(1-2):35-36.
13. Prunescu PP, Prunescu P, Krasinska M, Krasinsk ZA. Liver histological structure in adult European Bison. *Bison bonasus* (Linnaeus, 1758). Folia morphol. 2002;61(3):137–142.
14. Singh UB, Sulochana S. Hand book of Histological and Histochemical Techniques. Edn. 2nd, Premier Publishing House, 1996, 39-59.