



P-ISSN: 2349-8528

E-ISSN: 2321-4902

www.chemijournal.com

IJCS 2020; 8(1): 2689-2693

© 2020 IJCS

Received: 07-11-2019

Accepted: 09-12-2019

Jeevan KVeterinary College, Hebbal,
Bengaluru, Karnataka, India**Suguna Rao**Veterinary College, Hebbal,
Bengaluru, Karnataka, India**Satyanarayana ML**Veterinary College, Hebbal,
Bengaluru, Karnataka, India**Byregowda SM**Institute of Animal Health and
Veterinary Biologicals,
Bengaluru, Karnataka, India**Leena G**Veterinary College, Hebbal,
Bengaluru, Karnataka, India**Krishnamoorthy P**ICAR-NIVEDI, Bengaluru,
Karnataka, India**Corresponding Author:****Jeevan K**Veterinary College, Hebbal,
Bengaluru, Karnataka, India

International Journal of *Chemical Studies*

Anti-preneoplastic and anti-fibrogenetic effect of zinc oxide nanoparticles (ZnO NPs) against experimental hepatocarcinogenesis

Jeevan K, Suguna Rao, Satyanarayana ML, Byregowda SM, Leena G and Krishnamoorthy P

DOI: <https://doi.org/10.22271/chemi.2020.v8.i1ao.8675>

Abstract

To investigate the effects of zinc oxide nanoparticles (ZnO NPs) against hepatocarcinogenesis, the present study was conducted. To induce hepatocarcinogenesis rats with Diethylnitrosamine (DEN) at 100 mg/kg body weight intraperitoneally on Day 1 followed by 0.01 % DEN in drinking water ad libitum for 60 days. Zinc oxide nanoparticles as aqueous suspension was gavaged orally at a dose rate of 25 mg/kg body weight for 15 days prior to DEN treatment in ZnO NPs pre-treatment group and concurrently with DEN for 60 days in ZnO NPs concurrent treatment group. DEN induced severe hepatic damage and formation of preneoplastic altered hepatic foci by 30th day and severe fibrotic tissue proliferation with development of hepatic adenoma and carcinoma by 60th day. In pre-treatment and concurrent treatment groups, ZnO NPs reduced the extent of hepatic damage, prevented the formation of altered hepatic foci by 30th day and drastically reduced the extent of fibrotic tissue proliferation by 60th day which were determined through routine histopathology of hepatic tissue and special staining techniques alongside gross observation of liver.

Keywords: Hepatocarcinogenesis, ZnO NPs, DEN, altered hepatic foci, fibrosis

Introduction

During recent years, advances in nanobiotechnology/nanomedicine have opened new avenues in chemotherapeutics of cancer (Dai, 2016) [1]. Nanoparticles with their unique properties, are becoming increasingly important in modern cancer therapy and starting to overshadow traditional cancer therapies (Bisht and Rayamajhi, 2016) [2]. Zinc oxide nanoparticles (ZnO NPs) characterised by high catalytic efficiency, high adsorbing ability and capability to improve the oxidant state represent one such nanotechnological approach. With other additional properties such as biocompatibility, high selectivity and enhanced cytotoxicity, ZnO NPs may emerge as promising anticancer agent (Rani *et al*, 2017) [3].

Among various cancers in humans, hepatocellular carcinoma is one of the major malignant tumors causing more than 250,000 deaths annually worldwide. It is especially prevalent in the sub-Saharan areas of Africa and in South-eastern Asia, where HCC is closely associated with aflatoxin exposure and chronic viral hepatitis (Chaung *et al.*, 2000) [4]. Since the prognosis of HCC is extremely poor, more effective measures for chemoprevention are to be undertaken. Various *in vitro* studies have proven the effective properties of ZnO NPs against different cancer cell lines but its effects have not been addressed in *in vivo* condition until recently.

In the present study, diethylnitrosamine (DEN) was chosen for experimental induction of hepatocarcinogenesis in male Wistar Albino rats. DEN is a proven hepato-specific carcinogen predominantly affecting liver. The biochemical, morphological and histological changes induced by DEN in rats mimic human hepatocellular carcinoma (Macejova and Britko, 2001) [5]. Using this model, the anticancerous effects of ZnO NPs against hepatocarcinogenesis were evaluated.

Materials and methods

Experimental animals

Male Wistar albino rats of 8 weeks age (180-220 g) were procured from Indian Institute of Science, Bengaluru for the study.

They were housed in polypropylene cages (6 rats per cage) under standard laboratory conditions with a 12 hour dark/light cycle and offered with *ad libitum* rat pellet feed (Indian Immunologicals Pvt. Limited, Hyderabad) and clean drinking water. The experiment was performed according to CPCSEA, India guidelines after seeking approval from the Institutional Animal Ethics Committee (IAEC).

Sources of chemicals and drugs

DEN (Product number: N0756 – N-Nitrosodiethylamine liquid, 1 g/ml) ZnO NPs (Product number: 721077 ZnO nanoparticles dispersion, <100 nm particle size (TEM), ≤40

nm average particle size, 20 weight % in H₂O) were procured from Merck KGaA, Darmstadt, Germany. All other chemicals and reagents of analytical grade were procured from local sources.

Experimental design

The rats were acclimatized to standard laboratory conditions for 15 days. They were randomly divided into five groups each containing 6 rats, as shown below. Care was taken to maintain the intra-group and inter-group weight variations within 5-10 g and 10-15 g respectively.

Group I	Negative control
Group II	DEN control – Rats administered with DEN at 100 mg/kg intraperitoneally on Day 1 and subsequently through drinking water at 0.01 % v/v concentration for 60 days
Group III	ZnO NPs control – Rats administered with ZnO NPs (25 mg/kg/day) in normal saline orally for 60 days.
Group IV	Concurrent group – Rats administered with DEN and ZnO NPs simultaneously for 60 days.
Group V	Pre-treatment group – Rats administered with ZnO NPs at 25 mg/kg body weight for 15 days prior to treatment with DEN as in Group II and observed for 60 days.

Interim sacrifice of 3 rats /group was done on 30th day and terminal sacrifice of remaining rats was done on 60th day using ketamine hydrochloride anaesthesia. Liver samples for histopathology were collected in 10 % NBF and a portion of it was collected without any preservative and stored at -80 °C.

Histopathology

The tissues fixed in 10 % NBF were processed routinely by paraffin embedding technique and sectioned at 4-5 micron thickness using rotary type microtome and stained with Haematoxylin and Eosin (H&E), Mason's trichrome, Periodic Acid Schiff (PAS) for histopathological examination (Luna, 1968)^[6].

Results

Gross pathology

On gross examination, liver appeared normal in negative control and ZnO NPs control animals throughout the study period (fig 1. a,b). In DEN control animals, there was a progressive development of lesions from liver appearing pale and firm with rough granular surface involving all lobes on 30th day (fig 1. c) to appreciable surface nodularity and a few firm white foci on 60th day (fig 1. f) of experiment. However, the rats concurrently treated and pre-treated with ZnO NPs showed apparently normal liver on 30th day (fig 1. d,e) and by 60th day liver was slightly enlarged, pale and firm with rough granular surface involving one or two lobes (fig 1. g,h).

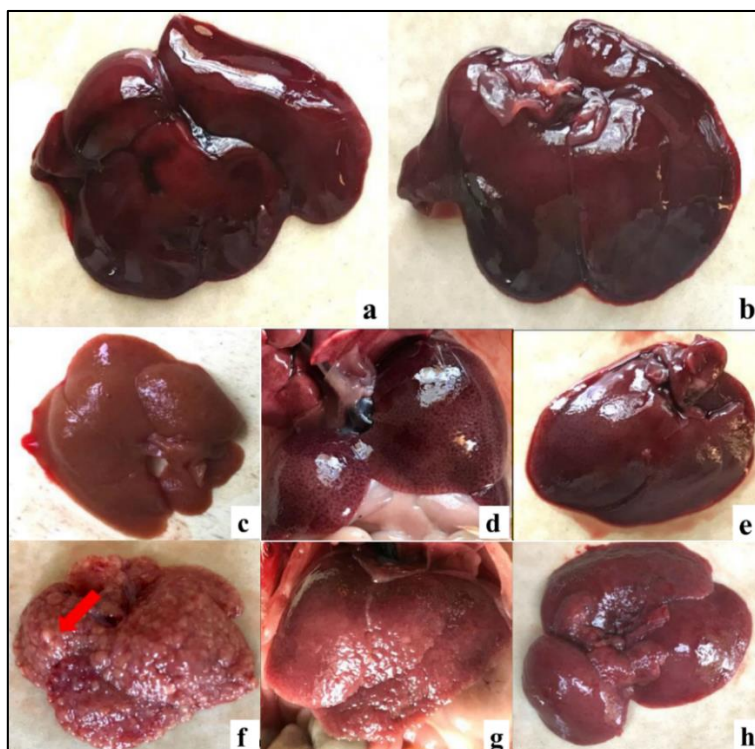


Fig 1: Gross appearance of livers from various groups on 30th and 60th day.

a and b – normal appearance of livers from negative control and ZnO NPs control respectively.

c – 30th day DEN group, pale colour and rough granular surface.

d,e – 30th day ZnO NPs concurrent and pre-treatment groups respectively, apparently almost normal with slight nutmeg appearance.

f – 60th day DEN group, severe surface nodularity with occasional white foci.

g, h – 60th day ZnO NPs concurrent and pre-treatment groups respectively, rough granular surface without nodularity.

Histopathology

Histopathological examination of liver tissues from control groups (Group I and III) showed normal cellular architecture throughout the study period.

On 30th day, liver sections from DEN control group revealed presence of numerous altered hepatic foci (AHF) such as eosinophilic, clear cell, basophilic and mixed types. These were associated with other dysplastic changes in hepatocytes like anisocytosis, anisonucleosis, prominent nucleoli and eosinophilic cytoplasmic inclusions along with highly appreciable oval cell hyperplasia. However, the livers from rats pre-treated and concurrently treated with ZnO NPs microscopically revealed maintenance of lobular structure with presence of toxic changes in the hepatocytes like hypertrophy with karyomegaly and homogeneous or granular cytoplasm at 30th day with pre-apoptotic cells and very few small sized altered hepatic foci. In occasional areas, mild oval cell proliferation and biliary hyperplasia was also observed.

By 60th day, complete loss of normal liver architecture with loss of normal hepatic parenchyma was observed in DEN control group. The liver tissue showed presence of numerous regenerative nodules surrounded by thick fibrous connective tissue. Amidst these nodules, there were few dysplastic

nodules with high cellular pleomorphism. Cystic dilatation and cholangiofibrosis were prominent. The development of hepatocellular adenomas and focal hepatocellular carcinoma was also observed by 60th day.

However, the livers from ZnO NPs treated groups showed multinodularity with hyperplastic and regenerative nodule formation surrounded by very minimal connective tissue. Occasional preneoplastic hepatic foci and mild oval cell proliferation were observed. There was no formation of adenoma or carcinoma in any of the animals treated with ZnO NPs.

Special staining for semi-quantification of lesions

The clear cell foci were positive for glycogen when stained with Periodic Acid Schiff. Based on the positive staining for glycogen, it was observed that the number of clear cell foci were minimal at 30th day of treatment in ZnO NPs treated groups in comparison with the positive control animals.

The amount of fibrous tissue proliferation in livers from various group was qualitatively analysed under Masson's trichrome staining which revealed decrease in the amount of fibrous tissue proliferation in ZnO NPs treated groups as compared with the DEN control animals.

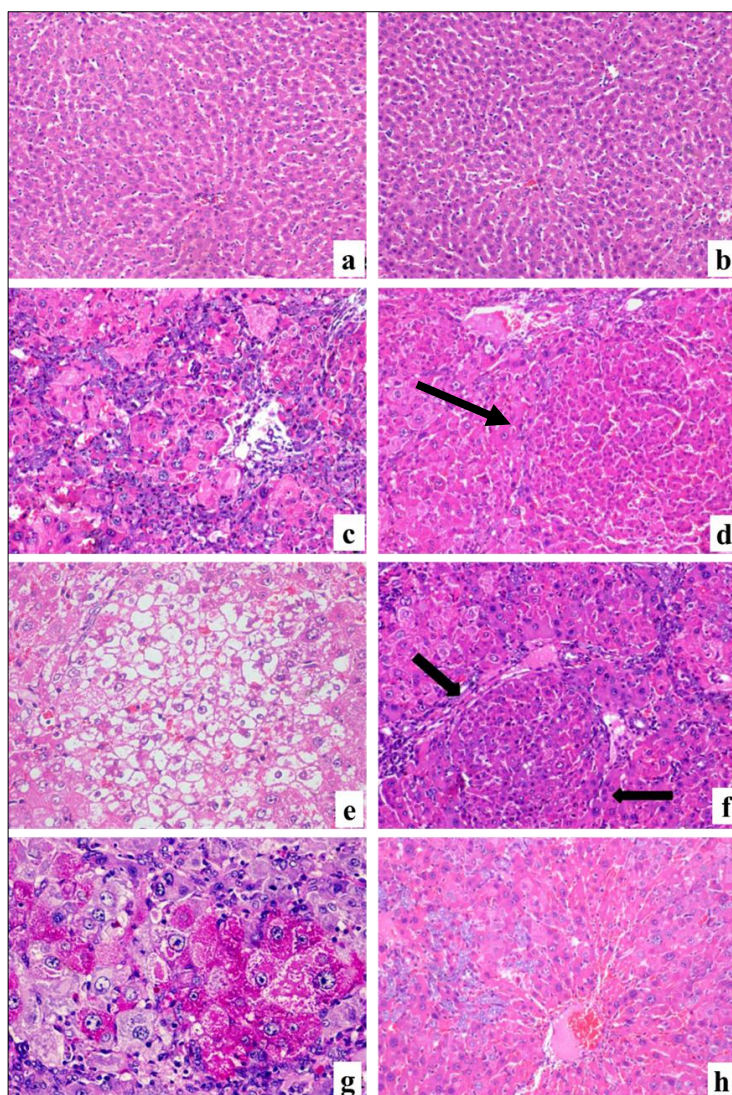


Fig 1: Microscopic findings of livers from various groups on 30th day.

a,b – Normal histology of liver in negative control and ZnO NPs control groups.

c – Severe damage of hepatic parenchyma with extensive oval cell proliferation in DEN control.

d,e,f – eosinophilic, clear cell and basophilic preneoplastic AHF respectively in DEN control.

g – Clear cell foci positive for glycogen under PAS staining.

h – ZnO NPs treatment group showing mild damage to hepatic parenchyma with minimal oval cell proliferation.

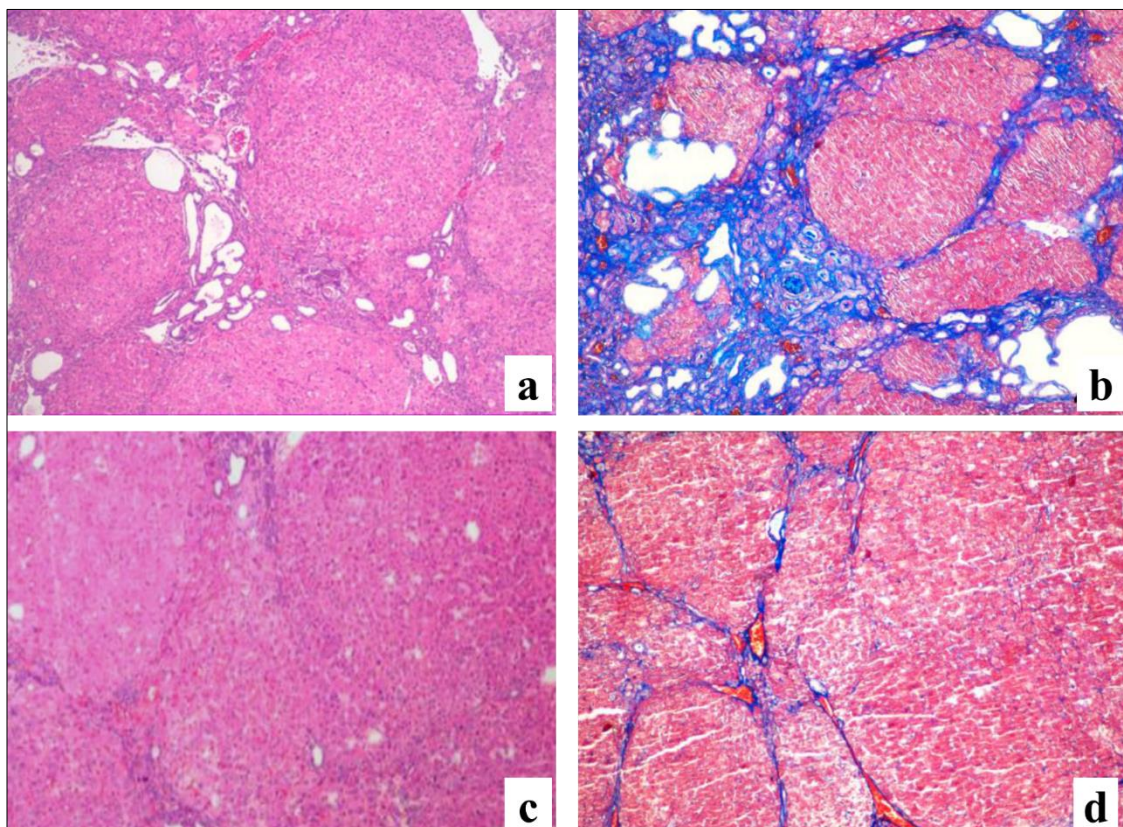


Fig 2: Microscopic findings of livers from various groups on 60th day.

a,b – DEN control liver showing severe fibrous tissue proliferation under H&E and Masson's trichrome staining respectively.
c,d – ZnO NPs treated liver showing minimal fibrous tissue proliferation under H&E and Masson's trichrome staining respectively.

Discussion

The occurrence of lesions on surface of liver grossly and formation of preneoplastic altered hepatic foci in liver of DEN treated rats by 30th day was considered as mainly due to the DNA damage through oxidative stress caused by DEN which causes perturbations in the nuclear enzymes involved in DNA repair/replication (Jagadeesh *et al.*, 2011) [7]. The glycogen positivity in the clear cell foci is attributable to the alteration in glucose metabolism caused by DEN in those cells. The less number of preneoplastic altered hepatic foci in ZnO NPs treated groups can be attributed to the antioxidant effect of ZnO NPs through quenching of the oxidants formed during DEN biotransformation in the liver by the Zn metallothioneins and maintenance of membrane integrity (Rana and Kumar, 2001, Grungreiff, 2002 and Rani *et al.*, 2017) [8, 9, 3].

The extensive fibrous tissue proliferation by 60th day was observed microscopically in the livers of DEN treated rats which was confirmed through Masson's trichrome staining. This was considered as a reparative mechanism against DEN induced hepatic damage where the damaged parenchyma was replaced by fibrous tissue. DEN causes increase in circulating TNF alpha level which plays an important role in fibrous tissue proliferation through signalling pathways. The minimal fibrosis in ZnO NPs treated livers could be attributed to the inhibition of production of inflammatory cytokines such as TNF alpha and interleukins such as IL-1 beta, IL-6 (Kim *et al.*, 2014 and Rani *et al.*, 2017) [10, 3]. Significant reduction in connective tissue proliferation in rat liver on zinc supplementation has also been reported by Grungreiff, 2002 [9] in various hepatotoxicities.

Conclusion

Based on the findings of the present study, it can be concluded that Zinc oxide nanoparticles have the anti-pre neoplastic and anti-fibrogenic properties when pre-treated at 25 mg/kg/day for 14 days prior to 60 day DEN treatment and concurrently treated with DEN at 25 mg/kg/day for 60 days.

References

1. Dai P, Yan TT, Yu XX, Bai XM, Wu MZ. Two-solvent method synthesis of NiO/ZnO nanoparticles embedded in mesoporous SBA-15: Photocatalytic properties study. *Nanoscale Res. Lett.* 2016; 11:226-232.
2. Bisht G, Rayamajhi S. ZnO Nanoparticles: A promising anticancer agent. *Nanobiomedicine.* 2016; 3:9-19.
3. Rani V, Verma Y, Rana K, Rana SVS. Zinc oxide nanoparticles inhibit dimethylnitrosamine induced liver injury in rat. *Chem. Biol. Interact.* 2017; S0009-2797(17):30967-30975.
4. Chuang SE, Kuo ML, Hsu CH, Chen CR, Lin JK, Lai GM *et al.*, Curcumin-containing diet inhibits diethylnitrosamine-induced murine hepatocarcinogenesis. *Carcinogenesis.* 2000; 21(2):331-335.
5. Macejova D, Brtko J. Chemically induced carcinogenesis: A comparison of 1-methyl-1-nitrosourea, 7,12-dimethylbenzanthracene, diethylnitroso-amine and azoxymethan models (Mini review). *Endocrine Regulations.* 2001; 35:53-59.
6. Luna LG. *Manual of Histopathological Staining Methods of the Armed Forces Institute of Pathology.* 3rd Edn, McGraw Hill Book Co., New York, 1968.
7. Jagadeesh MC, Sreepriya M, Bali G, Manjulakumari D. Protective effects of Embelin and Curcumin against diethylnitrosamine/ phenobarbital induced experimental

- hepatocarcinogenesis in rats. *International Journal of Life Sciences*. 2011; 5(1):51-56.
8. Rana SVS, Kumar A. Effect of cadmium and zinc metallothionein on methemoglobin and nitric oxide in dimethylnitrosamine treated rats. *Indian J Exp. Biol.* 2001; 39:487-489, 239.
 9. Grungreiff. Zinc in liver disease, *The Journal of trace elements in experimental medicine*. 2002; 15:67-78.
 10. Kim MH, Seo JH, Kim HM, Jeong HJ. Zinc oxide nanoparticles: A novel candidate for the treatment of allergic inflammatory diseases. *Eur. J Pharmacol.* 2014; 738:31-39.