International Journal of Chemical Studies

P-ISSN: 2349–8528
E-ISSN: 2321–4902
IJCS 2018; 6(6): 293-294

Received: 05-09-2018
Accepted: 07-10-2018

Naresh Kumar M
Teaching Veterinary Clinical Complex, Veterinary College, Shivamogga, KVAFSU, Karnataka, India

Tajunnisa M
Teaching Veterinary Clinical Complex, Veterinary College, Shivamogga, KVAFSU, Karnataka, India

Hanumantha Raju NS
Department of Veterinary Gynaecology and Obstetrics, Veterinary College, Shivamogga, KVAFSU, Karnataka, India

Mayakkannan Thippan
Department of Veterinary Anatomy, Veterinary College, Shivamogga, KVAFSU, Karnataka, India

Correspondence
Mayakkannan Thippan
Department of Veterinary Anatomy, Veterinary College, Shivamogga, KVAFSU, Karnataka, India

Evolution of antifungal activity of ivermectin as novel alternative therapies for dermatophytosis in Malnad Gidda cow

Naresh Kumar M, Tajunnisa M, Hanumantha Raju NS and Mayakkannan Thippan

Abstract
A study was undertaken to determine the antifungal activity of Ivermectin in ringworm infection in Malnad Gidda cow. Skin scraping collected from the cow which showed circumscribed erythematous grayish-white crusty lesions on the body. Direct Microscopic examination of scrapings using Lactophenol cotton blue revealed macroconidia of Trichophyton species. Four doses of Ivermectin were administered subcutaneously at seven days interval. Apparently there was 80% improvement in the condition after ivermectin administration. This study indicated that Ivermectin is used for the treatment of dermatophytosis in cattle instead of local or parenteral antifungal drugs.

Keywords: Ivermectin, Malnad Gidda and trichophyton spp

Introduction
Dermatophytosis, caused by *Trichophyton verrucosum*, is a disease that affects many species of livestock and occurs as an acute or chronic skin disease (Chermette *et al.*, 2008) [2]. Dermatophytes are surface parasites of keratinized tissue and hair of livestock and are communicable to man (Sharma *et al.*, 2010) [7].
Ivermectin is macrocyclic lactones are products or chemical derivatives of soil microorganisms belonging to the Streptomyces avermitilis fungus. The main uses of Ivermectin in treatment of intestinal helminthes infections as strongyloidiasis, onchocerciasis and heart worm also it is active agents in treatment of ectoparasites like ticks and lice (Omura, 2008) [8].
Dermatophytosis is very rare in the Malnad Gidda cow; therefore the aims of the present study are to determine the prevalence of bovine dermatophytosis and treatment of the infection in Malnad Gidda by Ivermectin.

Materials and Method
A Malnad Gidda cow aged 1½ years brought to Veterinary Clinical Complex, Shivamogga, with the history of hair loss, itching and other vital signs were normal. On physical examination of animal circular alopecic lesion noticed all over the body.
For microscopic examination, circumscribed skin lesion was disinfected using 70% ethyl alcohol to remove surface adhering microorganism and debris and allowed to dry. Edges of the lesions were scraped using blunt scalpel blade until the blood oozed. Hair from the affected lesion was also taken. The samples were treated with 10% potassium hydroxide (KOH) solution for dissolving debris and later centrifuged. Some portion of the sediment was taken on to the clean glass slide under sterile condition. Macroconidia of Trichophyton spp was revealed upon observation under 10X and 40X magnification of light microscope (Fig.1).

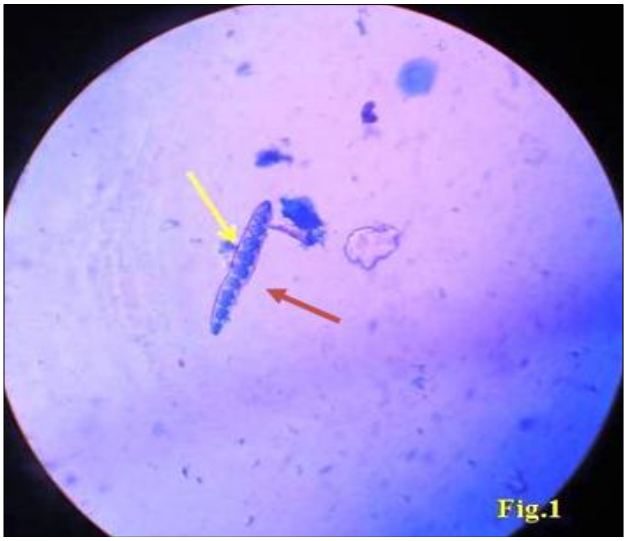

Fig 1: Microscopic picture showing Trichophyton spores (Red arrow) – 40x

Results and Discussion

The skin of affected Malnad Gidda cow showed discrete, circular, circumscribed lesion of variable size that covered with grayish-white crust. Removal of the crusts from the discrete circumscribed lesions revealed an alopecic, red and moist keratinized tissue. The skin lesions were mainly observed on the head, neck, shoulder, abdominal and brisket regions (Fig 2).The clinical signs observed in the present investigation were similar to the dermatophytosis in cattle as was reported by Chermette *et al.* (2008) [2]; Kirmizigul *et al.*, (2012) [5] and Swai and Sanka (2012) [9].

Fig 2: Malnad Gidda cow showing circumscribed skin lesion on the shoulder and flank region

In the present study, the0 dermatophytosis or ringworm is one of the commonest skin diseases in livestock farm animals such as cattle, buffalo and sheep. Several outbreaks of the disease have been reported in cattle (Ming *et al.*, 2006; Jameel *et al.*, 2015) [6, 4] and in sheep & goat as well (Jameel *et al.* 2014; Biswas *et al.*, 2015) [3, 1].

After confirmative diagnosis, the 1% of Ivermectin (Neomec) injection was administered subcutaneously at a dose rate of 200µg per kg along with injection Chlorpheniramine maleate 7 ml intramuscularly. The following treatment was done on the 8th, 15th and 22nd day. Condition of the affected lesions improved from 2nd injection onwards. Growth of hair noticed over the alopectic areas after complete treatment. This result did not have any side effects on the animal's health during the period of treatment.

These findings indicate that Ivermectin can also be successfully utilized in the treatment of dermatophytosis infections occurring in cattle. This study was agreed with Kirmizigul *et al.* (2012) [5] which proved the ability of Ivermectin in treatment of ringworm infection in cattle.

Conclusion

Derivative of Ivermectin are structurally similar to macrolide antibiotic and antifungal macrocyclic polyenes so, it could be used effectively in the treatment of bovine dermatophytosis, minimizing the duration and the cost of treatment.

Acknowledgment

The authors were thankful to Head, Veterinary Clinical Complex (VCC), Shivamogga, KVAFSU, Bidar.

References

1. Biswas MK, Debnath C, Mitra T, Baidya S, Pradhan S. Studies on dermatophytoses in sheep and goat in west Bengal, India. Indian Journal of Animal Health. 2015; 54(2):109-114.
2. Chermette R, Ferreiro L, Guillot J. Dermatophytoses in animals. Mycopathologia. 2008; 166(5-6):385-405.
3. Jameel GH, Minnat TR, Humadi AA, Ali Ibrahim AE. Hematological and Histopathological effects of Ivermectin in treatment of Ovine Dermatophytosis in Diyala Province-Iraq. International Journal of Science and Research. 2014; 3(11):1389-1394.
4. Jameel GH, Ahmed AA, Jalil OK, Dawood WS. Ivermectin activity in treatment of cattle Dermatophytosis. *Diyala* Agricultural Sciences Journal. 2015; 7(1):30-40.
5. Kirmizigul AH, Gokce E, Sahin M, Kiziltepe S, Buyuk F, Erkilic EE. Clinical effectiveness of Ivermectin on bovine Dermatophytosis. Kafkas Univ Vet Fak Derg. 2012; 18(3):523-526.
6. Ming PX, Ti YLX, Bulmer GS. Outbreak of Trichophyton verrucosum in China transmitted from cows to man. Mycopathologia. 2006; 161:225-228.
7. Sharma DK, Joshi G, Lakhotia RL, Sharma K. Canine dermatophytosis. Ind. Vet. J. 2010; 87:610-611.
8. Omura S. Ivermectin: 25 years and still going strong. International journal of antimicrobial agents. 2008; 31(2):91-98.
9. Swai ES, Sanka PN. Bovine Dermatophytosis caused by Trichophyton verrucosum: a case report. Vet. World. 2012; 5(5):297-300