



P-ISSN: 2349-8528

E-ISSN: 2321-4902

IJCS 2018; 6(6): 1564-1566

© 2018 IJCS

Received: 13-09-2018

Accepted: 16-10-2018

Ravi Dutt

Assistant Professor, Department of Veterinary Gynaecology and Obstetrics, College of Veterinary Sciences, Lala Lajpat Rai University of Veterinary and Animal Sciences, Hisar, Haryana, India

Amit Kumar

M.V.Sc Scholar, Department of Veterinary Gynaecology and Obstetrics, College of Veterinary Sciences, Lala Lajpat Rai University of Veterinary and Animal Sciences, Hisar, Haryana, India

Hariom

M.V.Sc Scholar, Department of Veterinary Gynaecology and Obstetrics, College of Veterinary Sciences, Lala Lajpat Rai University of Veterinary and Animal Sciences, Hisar, Haryana, India

Arjun V

M.V.Sc Scholar, Department of Veterinary Gynaecology and Obstetrics, College of Veterinary Sciences, Lala Lajpat Rai University of Veterinary and Animal Sciences, Hisar, Haryana, India

Jasmer Dalal

Ph.D., Scholar, Department of Veterinary Gynaecology and Obstetrics, College of Veterinary Sciences, Lala Lajpat Rai University of Veterinary and Animal Sciences, Hisar, Haryana, India

Gyan Singh

Assistant Professor, Department of Veterinary Clinical Complex, College of Veterinary Sciences, Lala Lajpat Rai University of Veterinary and Animal Sciences, Hisar, Haryana, India

RK Chandolia

Professor and Head, Department of Veterinary Gynaecology and Obstetrics, College of Veterinary Sciences, Lala Lajpat Rai University of Veterinary and Animal Sciences, Hisar, Haryana, India

Correspondence**Ravi Dutt**

Assistant Professor, Department of Veterinary Gynaecology and Obstetrics, College of Veterinary Sciences, Lala Lajpat Rai University of Veterinary and Animal Sciences, Hisar, Haryana, India

Hydroamnion associated with bull dog calf monstrosity in a Murrah buffalo: A case report

Ravi Dutt, Amit Kumar, Hariom, Arjun V, Jasmer Dalal, Gyan Singh and RK Chandolia

Abstract

A five years old 7 months pregnant Murrah buffalo in second parity suffering from hydroamnion presented to Veterinary Clinical Complex was treated successfully with cloprostenol, dexamethasone, estradiol benzoate, valethamate bromide on first day and oxytocin after 48 hours. The delivery of bull dog calf monster with excessive amount of amniotic fluid is reported here.

Keywords: Buffalo, bull dog calf monster, cloprostenol, estradiol benzoate, hydroamnion, oxytocin

Introduction

Hydroamnion is a dropsical condition of fetal sac in which there is excessive accumulation of fluid in amniotic sac and is associated with genetic or congenitally defective fetus (Roberts, 2004) [7]. Hydrollantois (excessive fluid accumulation in allantoic cavity) is much more common than hydroamnion, although the latter is always seen in association with specific fetal abnormalities such as the 'bulldog' calf in the Dexter (Noakes *et al.*, 2009) [6]. Hydroamnios is a rare pathological condition during gestation period and characterized by gradual accumulation of amniotic fluid with steady enlargement of abdomen in dam that is evident during last trimester (Drost, 2007) [2]. The etiological factors may include genetic factors (recessive autosomal genes), pituitary hypoplasia/aplasia, anencephaly, chemical agents or other drugs. The present report deals with hydroamnion associated with bull dog calf monstrosity in a seven months pregnant Murrah buffalo.

Case History and Observations

A five years old seven months pregnant Murrah buffalo (OPD No. 10-4505 dated 12.10.2018) in second parity was brought to Veterinary Clinical Complex, Hisar with bilateral distension of abdomen (Fig. 1), anorexia and respiratory distress. As per owner's statement the abdomen was increasing bilaterally in size for last one and half month. Per-rectal examination revealed distended uterus, weak fremitus and difficulty in palpation of the fetus. On per-vaginum examination the cervix was found to be closed. The animal was having fever (104.0^oF) which was relieved with Inj. Vetalgin[®] (Analgin, MSD Animal Health) 30 ml IM.

Treatment and Discussion

On the basis of history and gynaecological examination the animal was diagnosed to be suffering from hydroamnion. The animal was treated with Inj. Metrum[®] (Cloprostenol; Macwell Pharma) 2 ml IM, Inj. Dexona[®] (Dexamethasone; Zydus AHL) 10 ml IM, Inj. Epidosin[®] (Valethamate bromide; TTK) 10 ml IM, Inj. Avil[®] (Chlorpheniramine maleate; MSD Animal Health) 10 ml IM, Inj. Pregheat[®] (Estradiol benzoate; Virbac India) 2 ml IM, Inj. Mifex[®] (Calcium-magnesium-boro-gluconate; Novartis India Limited) 450 ml IV and Inj. Dextrose Normal Saline (Dextrose 5%; Fresenius Kabi) 5 litres IV. On second day per-vaginal examination revealed two fingers dilated cervix. Therefore, further medications included Inj. Epidosin[®] (Valethamate bromide; TTK) 10 ml IM, Inj. Dexona[®] (Dexamethasone; Zydus AHL) 10 ml IM, Inj. Pregheat[®] (Estradiol benzoate; Virbac India) 2 ml IM and Inj. Dextrose Normal Saline (Dextrose 5%; Fresenius Kabi) 5 litres IV. After 24 hours, per-vaginum examination witnessed complete dilatation of cervix and Inj. Evatocin[®] (Oxytocin; Neon laboratories) 10 ml in 1 litre of normal saline was administered intravenously.

After around 30 minutes of oxytocin therapy, large quantity of syrupy, viscid amniotic fluid oozed out (Fig. 2) and immediately, dextrose normal saline (Dextrose 5%; Fresenius Kabi) 3 litres IV were administered.

Subsequently, a congenitally malformed fetus with improper skin development and stumpy extremities was delivered by mutation. The fetus was described as ‘bull dog calf monster’ (Fig. 3). The supportive treatment included Inj. Mifex® (Calcium-magnesium-boro-gluconate; Novartis India Limited) 450 ml IV, Inj. Evatocin® (Oxytocin; Neon laboratories) 10 ml in 1 litre of Normal Saline IV and Inj. Cefwell forte® (Cefoperazone plus sulbactam; Macwell pharma) 4.5 g IM. The placenta was removed gently by manual traction. The post-partum treatment advised for five days included Inj. cefwell forte® (Cefoperazone plus sulbactam; Macwell pharma) 4.5 g IM, Inj. Avil® (Chlorpheniramine maleate; MSD Animal Health) 10 ml IM, Inj. Megludyne® (Flunixin meglumine; Virbac Animal Health India Pvt Ltd.) 20 ml IM, Inj. Tcee® (Ascorbic acid; Titanic Pharmaceuticals Pvt. Ltd.) 30 ml IM, Inj. Metrogyl® (JB Chemicals; Metronidazole 2500mg/500 ml) IV and Inj. Dextrose Normal Saline (Dextrose 5%; Fresenius Kabi) 3 litres IV for five days. After expulsion of fluid, it was found that last two floating ribs of left side of the dam were broken, which resulted in great respiratory distress to the animal (Fig. 4). It is presumed that it might have occurred due to over-distension of abdomen and pressure over the ribs due to excessive accumulation of fluid in the abdominal cavity. The fetus was small in size and with gross morphological defects. The fetus had stumpy limbs, deformed head, face and skin without hairs indicating bull dog calf monstrosity. The uneventful recovery of the dam was noticed.

Hydroamnion is seen commonly in cattle (Noakes *et al.*, 2009) [6] and is always seen in association with specific fetal anomalies especially the facial defects (Dhaliwal *et al.*, 1992). In the defective fetus, swallowing is impaired leading to gradual increase in the amniotic fluid to 5-30 gallons compared to 1-2 gallons in normal cows (Roberts, 2004) [7]. Mehra *et al.* (2012) [4] reported hydroamnion in a Murrah buffalo associated with deformed fetal maxilla and mandible giving appearance like the “trunk of elephant’s calf”. The treatment of dropsy of fetal membranes is directed to evacuate the uterus by caesarean section or induction of parturition process to terminate the pregnancy. If a large volume of allantoic fluid in the uterus is expelled rapidly, circulatory shock can develop (Misri and Singh 2001) [5]. In the case reported here, the combined therapy of cloprostenol, dexamethasone, valethmate bromide and estradiol benzoate followed by oxytocin after 24 hours and proper fluid therapy could avoid the shock to the animal. Sathya *et al.* (2006) [8] and Honparkhe *et al.* (2010) [3] have reported similar cases of hydroamnion associated with fetal defects in buffaloes. Conclusively, the case of hydroamnion accompanying with bull dog calf monstrosity in a Murrah buffalo was handled successfully with hormonal and fluid therapy without any post-partum complication.




Fig 1: Bilateral distension in hydro-amniotic Murrah buffalo



Fig 2: Passage of syrupy, viscid amniotic fluid

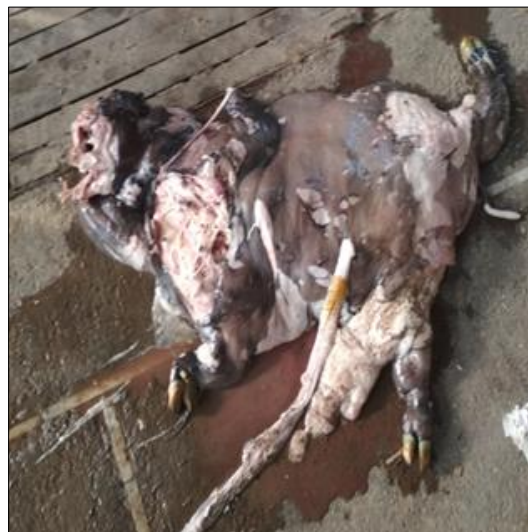

Fig 3: Bull dog calf monster



Fig 4: Broken ribs in the affected dam

References

1. Dhaliwal GS, Prabhakar S, Singh P, Sharma RD. Hydroamnion in association with Diprosopus fetus in crossbred cattle. *Indian Vet. Med. J.* 1992; 16:220-222.
2. Drost M. Complications during gestation in the cow. *Theriogenology.* 2007; 68:487-491.
3. Honparkhe M, Ghuman SPS, Kumar A. Prolonged gestation in a buffalo with hydroamnios associated with fetal monster: A case report. *Indian J Anim. Reprod.* 2010; 31:89-90.
4. Mehra US, Dutt R Seema. Successful management of hydroamnion in a Murrah buffalo. *Indian Journal of Anim. Reprod.* 2012; 33(2):90-91.
5. Misri J, Singh N. Hydrallantois in a Goat. *Ind. Vet. J.* 2001; 78:255-256.
6. Noakes DE, Parkinson TJ, England GCW. *Veterinary Reproduction and Obstetrics*, 9th Edn. Saunders Elsevier. 2009, 141.
7. Roberts SJ. *Veterinary Obstetrics and Genital diseases.* 2nd Edn. CBS Publishers and Distributors, 2004, 180.
8. Sathya A, Mahajan A, Prabhakar S. Dystocia in a buffalo due to fetal monster accompanying hydrops amnii. *Indian J Anim. Reprod.* 2006; 27:96-97.