International Journal of Chemical Studies

P-ISSN: 2349–8528
E-ISSN: 2321–4902
IJCS 2018; 6(2): 2574-2578

Received: 23-01-2018
Accepted: 26-02-2018

Anjali Singh
Department of Veterinary Medicine, College of Veterinary Science and A.H., N.D.V.S.U, Jabalpur (M.P.), India

Amita Tiwari
Department of Veterinary Medicine, College of Veterinary Science and A.H., N.D.V.S.U, Jabalpur (M.P.), India

PC Shukla
Department of Veterinary Medicine, College of Veterinary Science and A.H., N.D.V.S.U, Jabalpur (M.P.), India

Brejesh Singh
Department of Veterinary Medicine, College of Veterinary Science and A.H., N.D.V.S.U, Jabalpur (M.P.), India

DK Gupta
Department of Veterinary Medicine, College of Veterinary Science and A.H., N.D.V.S.U, Jabalpur (M.P.), India

Priya Maravi
Department of Veterinary Medicine, College of Veterinary Science and A.H., N.D.V.S.U, Jabalpur (M.P.), India

Manu Jaiswal
Department of Veterinary Medicine, College of Veterinary Science and A.H., N.D.V.S.U, Jabalpur (M.P.), India

Amir Amin Sheikh
Department of Veterinary Physiology and Biochemistry, College of Veterinary Science and A.H., N.D.V.S.U, Jabalpur (M.P.), India

Rakshanda Bhagat
Division of Veterinary Medicine, F.V.Sc and A.H., Sher-e-Kashmir University of Agricultural Sciences and Technology of Jammu, R.S. Pura, Jammu, (J&K), India

Correspondence
Anjali Singh
Department of Veterinary Medicine, College of Veterinary Science and A.H., N.D.V.S.U, Jabalpur (M.P.), India

Methicillin resistant *Staphylococcus aureus* in equine: An emerging disease

Anjali Singh, Amita Tiwari, PC Shukla, Brejesh Singh, DK Gupta, Priya Maravi, Manu Jaiswal, Amir Amin Sheikh and Rakshanda Bhagat

Abstract
Methicillin resistant *staphylococcus aureus* infection can represent a hazard for equine health, and supports the opinion that inappropriate administration of antimicrobials and hospitalization/surgery represent risk factors for MRSA colonization and infection in horses. Methicillin-resistant *Staphylococcus aureus* was first isolated in 1960. Equine MRSA infection is an important emerging zoonotic and veterinary disease. Usually colonizes in the anterior nares, skin and mucous membrane and causes infection in immunocompromised patients. MRSA is of two types: hospital associated MRSA or community associated MRSA. Considering antimicrobial therapy of animals infected with MRSA, the risk for further development of resistance in the infecting strain needs to be considered. The choice of the antimicrobial should always be based on susceptibility testing. Many equine MRSA are still susceptible to commonly used 'routine' antimicrobials. Diagnosis can be done by isolation, disc diffusion test, cefoxitin disk screen test, latex agglutination test, etc. For the detection of mecA (methicillin resistance) and femA (S. aureus specific) genes, a multiplex PCR performed using primers.

Keywords: Equine, MRSA, PCR, *Staphylococcus aureus*

Introduction
Staphylococcus aureus is one of the most common pathogens among humans and animals. It was first described by Sir Alexander Ogston in 1882 and the German physician Friedrich J Rosenbach. It is a very successful bacterium and has shown a continuous evolution in terms of antibiotic resistance from the mid-1940s. One problematic trait of *Staphylococcus aureus* is its tendency to become resistant to antibiotics of which the particular concern is methicillin-resistant *Staphylocoocus aureus* (MRSA). It is resistant to all beta-lactam antibiotics (penicillin and cephalosporin families) and often many other antibiotics. This makes methicillin resistant *Staphylococcus aureus* infections more difficult to treat.
Methicillin-resistant *Staphylococcus aureus* was first isolated in 1960, after the introduction of semisynthetic penicillins in the clinical practice and soon became a worldwide health problem, spreading in hospital settings. MRSA is an emerging zoonotic pathogen. It is a multiple drug resistant organism that is an important cause of disease in humans. The growing prevalence of MRSA in some occupations and exposure groups is troubling, especially in light of evidence that MRSA moves freely between animals and humans. Concurrent with movement of MRSA into humans MRSA infection and colonization are increasingly reported in animals.
Equine MRSA infection is an important emerging zoonotic and veterinary disease. First discovered in 1989, MRSA has clearly emerged as an important pathogen in equine clinics, causing both carriage (colonization) and infections in patients, personnel and people. Nasal MRSA colonisation has also been identified as a risk factor for development of MRSA infection in horses admitted to a veterinary hospital (Weese *et al.*, 2005) [1]. Further, zoonotic transmission of MRSA to human subjects working with horses has been reported. Therefore, prevention of MRSA colonisation and eradication of MRSA on farms is desirable.

Mechanism of Development of MRSA
Staphylococcus aureus is a Gram positive opportunistic pathogen of humans and animals. It usually colonizes in the anterior nares, skin and mucous membrane and causes infection in immunocompromised patients. About 12% nasal carriage and 3% skin carriage of MRSA in 67 horses at an equine hospital in Canada was found by Baptiste *et al.* (2005) [2].

This occurrence is termed as "colonization," as the bacteria are present without causing any problem. A smaller number also colonizes in the intestinal tract or on the skin.

Methicillin resistance is mediated by the production of an altered penicillin-binding protein (PBP2a), which confers resistance to all β-lactam antimicrobial agents. The gene that encodes this altered PBP is *mecA* which resides on a large, mobile genetic element called the staphylococcal chromosomal cassette *mec* (SCC*mec*).

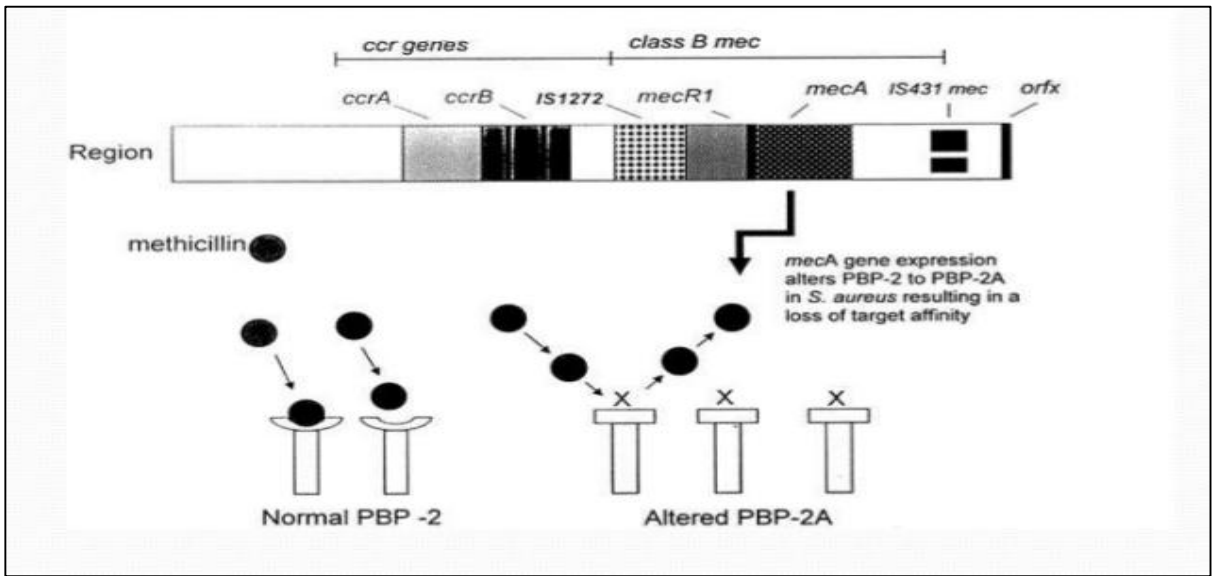

Fig 2: showing mechanism of development of MRSA

Types of MRSA

MRSA infections often present differently at the epidemiological and molecular levels. So, there are two types of MRSA infections that usually occur with different risk factors like history, age, infection type and resistance patterns. Because of these differences MRSA infections have been classified as either hospital associated MRSA or community associated MRSA.

Hospital associated Methicillin resistant *Staphylococcus aureus*

Hospital-associated methicillin resistant staphylococcus aureus (HA-MRSA) have been known as nosocomial pathogens for decades. MRSA are regarded as HA-MRSA when infections caused by them are likely to be acquired in healthcare centres, when they emerge at least 48 hour after admission in patients having particular risk factors such as prolonged hospital stay, prolonged antibiotic treatment, surgical interventions and /or close contact with MRSA positive individuals.

According to Anderson *et al.* (2009) [3], HA infections accounted for 50.9% (58/114) of the total cases at veterinary hospitals. HA infections were identified between 48 hours and 170 days after admission into the hospital. The most common 6complaints for horses that developed hospital acquired infection were colic (29/58, 50.0%), wounds (7/58, 12.1%) and lameness or hernia (3/58, 5.2% each).

Community acquired Methicillin resistant *Staphylococcus aureus*

Infections present upon admission and those detected <48 h after admission were classified as community associated (CA) MRSA. These community-acquired MRSA infections are less broadly resistant to antimicrobial agents than are HA MRSA. CA-MRSA infection may present as a red, swollen, painful site with drainage while those for horses that had or developed community acquired infections were wounds (10/56, 17.9%), incision infections (8/56, 14.3%) and septic joints (5/56, 8.9%). CA infections accounted for 49.1% (56/114) of cases according to Anderson *et al.*, (2009) [3].

Transmission

It was first thought that the transmission of MRSA was solely from human to horse, with MRSA colonization and infection typically occurring with contact between the hands of the human and anterior nares (nostrils) of the horse. As per AVMA, (2009) [4] MRSA can be transmitted in both directions, from horse to human (zoonotic) and human to horse (reverse zoonosis).

Prevalence of MRSA

Anzai *et al.* (1991) [5] isolated 15 MRSA strain for the first time from 13 metritis affected mares in Hidaki district, Japan. A retrospective case study was performed by Anderson *et al.* (2009) [3] on 115 horses admitted to 6 participating veterinary teaching hospitals in Canada and the United States between 2000 and 2006 and reported a prevalence of 50.9% HA and 49.1% CA MRSA. Infection of surgical incisions was most frequently reported (38.0%) Overall 83.8% cases survived to discharge. Loeffer *et al.* (2011) [6] performed a study in the

Greater London area among healthy and veterinary-treated horses and the result revealed that 3 horses were carrier among 152 horses tested for MRSA.

Eede *et al.* (2012) [7] conducted nasal and perianal MRSA screening of 189 horses on 10 farms in East- and West-Flanders, Belgium and found only one horse (0.53%) from one farm (10%) tested positive in the nose. No traceable literature on the prevalence of MRSA in equine in India is available however; many scientists have reported MRSA in other animal species. According to Kumar *et al.* (2016) [8] the prevalence of MRSA in a study conducted on apparently healthy cattle and buffalo of Institutional Livestock Farm Complex, Bihar Veterinary College (BVC), Patna, and from Skin and nasal swab samples (136) of patients coming to teaching veterinary clinical complex of BVC, Patna was 28.57% and 34.28% in cattle nasal and skin swab, respectively, with an overall prevalence of 31.43% MRSA among cattle whereas buffalo nasal and skin sample showed MRSA prevalence of 54.55% and 39.4%, respectively. Shrivastav *et al.* (2017) [9] had reported 16.47% prevalence rate of MRSA in mastitis affected dairy cattle in Jabalpur MP.

Clinical Signs

Clinical MRSA infections can occur as sporadic cases or in outbreaks, involving a wide range of opportunistic infections. The clinical syndrome in horses is somewhat similar to that in humans. They colonize the nares and gastrointestinal tract causing subclinical infection. Infections can vary and range from superficial to deep infections. Superficial infections include dermatitis, wound or incisional infections, joint or tendon sheath infections, and phlebitis. Deep infections include pneumonia, metritis, umbilical abscesses, scirrhous cord, sinusitis, osteomyelitis, mastitis and septicemia. Joint infection, skin infection and soft tissue infections are most common in community-onset cases, with surgical site infections predominating in hospitalized horses.

Anderson *et al.* (2009) [3] found that colic was the most common presenting complaint (29/115, 25.2%), followed by wounds (18/115, 15.7%) and incision infections (10/115, 8.7%). Sites of MRSA infection included surgical incisions (44/115,38.3%), other skin and soft tissue infections (24/115, 20.9%), joints (11/115, 9.6%), bone/tendon (9/115, 7.8%), I/V catheter sites (9/115, 7.8%) and lungs (5/115, 4.3%), as well as guttural pouch, sinus, nose, eye, trachea, uterus, udder and blood stream infections (<2.7% each). All animals which encounter MRSA do not develop clinical signs or illness. While research is ongoing, it appears that only a small percentage become ill, while most eliminate the organism or become colonized without developing clinical signs.

Diagnosis

Diagnosis should involve the identification of coagulase-positive *Staphylococci* to the species level, and all *Staphylococcus aureus* isolates should then be tested for oxacillin resistance, since methicillin is less stable *in vitro*.

Identification of Organism

Staphylococcus aureus (including MRSA strains) are cluster forming, facultative aerobic, Gram-positive cocci with intrinsic ability to ferment carbohydrates, producing white to deep yellow pigmentation on solid culture media. They also ferment mannitol turning mannitol salt agar yellow. The organisms produce deoxyribonuclease (DNase) and catalase enzymes and coagulase proteins used for their identification (Adetayo *et al.*, 2014) [10].

Rapid Culture

Boyle *et al.* (2017) [11] have used chromogenic agar for detecting MRSA, which is rapid culture and contains media substrates that change colour in the presence of *S. aureus*; selectivity for MRSA is achieved by incorporation of antibiotics into the agar. MRSA isolates give mauve colonies on chrom agar-MRSA plates. Use of such agar allows identification of MRSA from primary isolation plates within 24 to 48 hours, obviating the need for additional subcultures or biochemical tests

Disc Diffusion Test

Using Mueller Hinton agar (MHA) plates, MRSA strains exhibit resistance to oxacillin or methicillin (1 or 5 µg/disc: zone of inhibition < 14mm in diameter used as marker for all β-lactams).

Cefoxitin disk screen test

All methicillin resistant *Staphylococcus aureus* (MRSA) isolates carry the *mecA* gene, which confers resistance to all beta-lactam antibiotics, including cephalosporins and carbapenems. Cefoxitin is used because it is a more potent inducer of *mecA* expression than other agents such as oxacillin and the test results are relatively easy to interpret. The test involves incubating a lawn of the test isolate on Mueller Hinton agar with 2% sodium chloride under standardized conditions with a cefoxitin disk (30 mcg). According to the Clinical and Laboratory Standards Institute (CLSI), a zone of growth inhibition around the Cefoxitin disk of ≥22 mm rules out MRSA; a zone size <22 mm indicates that the *mecA* gene is present and the isolate should be reported as MRSA.

Latex agglutination test

Weese *et al.* (2005) [1] have used positive tube coagulase test or latex agglutination test for the diagnosis of MRSA in horse. MRSA-Screen consists of a latex reagent sensitized with monoclonal antibody against PBP2' together with reagents to rapidly extract PBP2' from the bacterial membranes of MRSA.

Detection of mec*A* gene by PCR

For the detection of mecA (methicillin resistance) and femA (S. aureus specific) genes, a multiplex PCR performed using primers.

Clinical management of MRSA

For infected horses

Non-antimicrobial management

A fast and accurate diagnosis is essential for the management of MRSA infections. Therefore, all postoperative infections need to be cultured routinely. In addition, non-healing wounds and infections not responding to antimicrobial therapy should be suspected. Failure to detect MRSA at an early stage can lead to suboptimal treatment of patients and to late identification of an outbreak, facilitating the spread of MRSA. Local treatment with antiseptics such as glycerol, chlorhexidine or povidone iodine can be used in wound infections. However, detailed studies on the efficacy of such compounds in MRSA-infected horses are not currently available. Treatment of mares by uterus insufflations with an ozone oxygen mix at concentrations of 80 µg/ml after positive identification of MRSA in endometrial swabs showed good results, with pregnancy being achieved afterwards (Kempchen *et al.*, 2013) [12].

Antimicrobial treatment in infected horses

When considering antimicrobial therapy of animals infected with MRSA, the risk for further development of resistance in the infecting strain needs to be considered. The choice of the antimicrobial should always be based on susceptibility testing. Many equine MRSA are still susceptible to commonly used 'routine' antimicrobials.

Vancomycin

The only effective drug against MRSA species is glycopeptide. Of the glycopeptides, vancomycin is the only one used in veterinary medicine. Orsini *et al.* (2005) [13] had used vancomycin for treatment of methicillin-resistant staphylococcal infections in 15 horses with a dose rate of 7.5 mg/kg q8hour, administered by intravenous infusion over 30 min. The calculated dose of vancomycin was added to sterile saline or other fluids and infused IV over 30 min. The dosage was typically 7.5 mg/kg q8h, although it ranged from 7.5 mg/kg q12h to 12.5 mg/kg q12h. Thus, although most of the horses received 22.5 mg/kg daily, the total daily dose ranged from 15 to 25 mg/kg, depending on whether the drug was given every 8 or every 12 h. The average duration of therapy with vancomycin was 10 d (range, 5 to 45 d). No adverse effects were reported, even in the horse that received Vancomycin for 45 d. Concurrent administration of an Aminoglycoside caused no adverse effects.

Oxazolidinones

Linezolid is the first in the class of oxazolidinones to be used in medicine. It is currently being used in people to treat vancomycin resistant gram-positive infections caused by streptococci, as well as MRSA. Glycyclines is the new class of antibiotic with activity against susceptible or multidrug-resistant staphylococci. Streptogramins, dalfopristin and daptomycin are antibiotics that are used in human medicine for cases of MRSA. The efficacy and safety of antimicrobials that are critical for MRSA treatment in human medicine, e.g. Linezolid and Teicoplanin have not been assessed in horses and similarly in livestock as there are ethical concerns about using them in veterinary medicine. Therefore the use of these antimicrobials is not advisable.

For colonized horses

Non-antimicrobial management

Means of decontaminating colonized animals can be tried. For example, horse can be bathed with 2% to 3% chlorhexidine or with a benzoyl peroxide shampoo, using it more aggressively every other day before trying a more expensive injectable or oral antiobiotic to treat the infection.

Antimicrobial Management

Information on the antimicrobial treatment of colonized horses is scarce. Colonization can be eliminated if proper measures are taken to prevent re-infection from other horses, people and the environment.

- Antimicrobial therapy should be reserved for persistent colonizations or for those cases where other control measures are impossible.
- Applying topical antimicrobials to the mares of horses seems unpractical, although nebulization (e.g. with Amikacin) might be an alternative. Safety and efficacy of this therapy needs to be further evaluated before it can be recommended.
- More serious superficial infections such as joint infections and deep infections should be treated with systemic antimicrobials.
- Selection of antimicrobials should be based on culture and susceptibility testing, as the susceptibility patterns vary widely among isolates.

Prevention

- .It is recommended that patients diagnosed with or suspected of MRSA infections are isolated in order to minimize the risk of nosocomial and zoonotic transmission.
- Infected horses should only be handled using contact precautions such as protective outerwear, e.g. overalls, aprons or coats and boots or overshoes that are not worn elsewhere, gloves and masks.
- Transmission of the organism by the hands is thought to be an important route of transmission within human and veterinary hospital settings. Therefore, hand hygiene should be an essential part of any infection control programme.
- Environmental transmission may be of greater importance in stables than in hospitals as horse stables are often very dusty.
- Routine screening of all horses before admission in order to identify colonized or infected animals could help to prevent the spread of MRSA.
- Furthermore, the owners visiting their infected animal should not visit other patients at the clinic.

Conclusion

Methicillin resistant staphylococcus aureus infection can represent a hazard for equine health, and supports the opinion that inappropriate administration of antimicrobials and hospitalization/surgery represent risk factors for MRSA colonization and infection in horses. The environmental contamination could play an important role in the dissemination and maintenance of MRSA strains over time, highlighting the importance of applying effective biosecurity and infection control practices at both the stable and hospital level. Transmission of MRSA between different hosts as well as between different ecological niches should be regarded as a major ''One Health'' problem.

Reference

1. Adetayo TO, Deji-Agboola AM, Popoola MY, Atoyebi TJ, Egberongbe KJ. Prevalence of methicillin resistant Staphylococcus aureus from clinical specimen in Ibadan, Nigeria. Int J Eng Sci, 2014; 3:1-11.
2. Anderson MEC, Lefebvre SL, Rankin SC, Aceto H, Morley PS, Caron JP. *et al.* Retrospective multicentre study of methicillin resistant Staphylococcus aureus infections in 115 horses. Equine Vet J, 2009; 41:401-405.
3. Anzai T, Kamada M, Kanemaru T, Sujita S, Simizu A, Higuchi T. Isolation of methicillin resistant Staphylococcus aureus (MRSA)from mares with metritis and its zooepidemiology. J Equine Med, 1996; 7:7-11.
4. AVMA. Methicillin Resistant Staphylococcus aureus online https://www.avma.org. 2009.
5. Baptiste K, Williams K, Willams N, Wattret A, Clegg P, Dawson S, *et al.* Methicillin-resistant Staphylococci in companion animals. Emerging Infect Disease, 2005; 11:1942-1944.
6. Boyle AG, Rankin SC, Duffee LA, Morris D. Prevalence of methicillin resistant Staphylococcus aureus from

Equine Nasopharyngeal and Guttural Pouch Wash Samples. J Vet Med, 2017; 31:1551-1555.
7. Eede AVD, Martens A, Feryn I, Vanderhaeghen W, Urszula L, Gasthuys F, *et al.* Low MRSA prevalence in horses at farm level. Biomed Cent Vet Res, 2012; 8:1-4.
8. Kempchen S, Lenk S, Behrendt D, Mayer V, Gremmes S. Case report of the treatment of two mares by uterus insufflation with an ozone oxygen mix after positive test results for MRSA in endometrial swabs. Tieraerztliche Umschau, 2013; 68:546-550.
9. Kumar A, Kaushik P, Kumar P, Kumar M. Prevalence of methicillin-resistant Staphylococcus aureus skin and nasal carriage isolates from bovines and its antibiogram. Vet world, 2017; 10:593-597.
10. Loeffler A, Pfeiffer DU, Lindsay JA, Soares RJ, Lloyd DH. Prevalence of and risk factors for MRSA carriage in companion animals: a survey of dogs, cats and horses. Epidem and Infect, 2011; 139:1019-1028.
11. Orsini JA, Parsons CS, Stine L, Haddock M, Ramberg CF, Benson CE, *et al.* Vancomycin for the treatment of methicillin-resistant staphylococcal and enterococcal infections in 15 horses. J Vet Res, 2005; 69:278-286.
12. Shrivastava N, Sharma V, Nayak N, Shrivastava AB, Sarkhel BC, Shukla PC *et al.* Prevalence and characterization of methicillin-resistant Staphylococcus aureus (MRSA) mastitis in dairy cattle in Jabalpur, Madhya Pradesh. J Anim Res, 2017; 7:77-84.
13. Weese JS, Rousseau J, Dargatz J, Willey M, McGeer AJ, Low DE. Community-associated methicillin-resistant Staphylococcus aureus in horses and humans who work with horses. J Amer Vet Med Assoc, 2005; 226:581-583.