



P-ISSN: 2349-8528

E-ISSN: 2321-4902

IJCS 2017; 5(6): 842-843

© 2017 IJCS

Received: 25-09-2017

Accepted: 29-10-2017

K Sukandhiya

Technical assistant, College of Poultry Production and Management, Hosur -635 110, Tamil Nadu, India

K Mani

Dean, College of Poultry Production and Management, Hosur - 635 110, Tamil Nadu, India

K Rajendran

Assistant Professor, Veterinary College and Research Institute, Namakkal - 637 002, Tamil Nadu, India

K Sangli Vikram Kumar

Assistant Professor (Animal Husbandry), The Indian Agriculture College, Radhapuram-627 111, Tamil Nadu, India

U Prabhakaran

Veterinary officer, Venkateswara Hatcheries Private Limited, Namakkal-637 001, Tamil Nadu, India

T Sasidhar

Technical Sales Officer, Venkateswara Hatcheries Private Limited, Namakkal-637 001, Tamil Nadu, India

Correspondence**K Sukandhiya**

Technical assistant, College of Poultry Production and Management, Hosur -635 110, Tamil Nadu, India

Influence of dietary supplementation of Sodium diformate on the intestinal Histo: morphology of broilers in environmentally controlled housing system

K Sukandhiya, K Mani, K Rajendran, K Sangli Vikram Kumar, U Prabhakaran and T Sasidhar

Abstract

A biological experiment was conducted to find out the influence of dietary supplementation of Sodium diformate (NDF) at 0, 0.05, 0.10, 0.15 and 0.20 per cent level and oxytetracycline at 0.02 per cent level on the intestinal histo-morphology of commercial broilers in environmentally controlled housing system. The result of the experiment revealed that dietary inclusion of sodium diformate had significant influence on the intestinal villi length of broilers reared in environmentally controlled housing system. Formic acid and their salts are well known to improve productivity by acting against pathogens, decrease pressure on the bird's immune system, which makes more nutrients available for productive functions such as growth. The double sodium salt of formic acid, having the same antimicrobial properties of formic acid reduces the impact of pathogenic bacteria in the gut of broilers and thereby improved the production performance.

Keywords: villi length, broilers, sodium diformate, environmentally controlled housing

Introduction

A biological experiment was conducted by using 300 day old, sex separated commercial broiler chicks belonging to single hatch. These chicks were randomly grouped into 6 treatments with 5 replicates of 10 chicks in each. All the birds were reared under standard management practices in an environmentally controlled house up to five weeks of age. Totally six experimental diets were prepared by adding sodium diformate (NDF) at 0, 0.05, 0.10, 0.15, and 0.20 per cent level and oxytetracycline at 0.02 per cent level in the basal broiler diet and fed to the broilers up to the end of the fifth week of experimental period. At the end of the study period (fifth week of age), two birds (one male and one female) from each replicate of the treatment group were randomly picked up and slaughtered. The intestine samples taken from duodenum portion were preserved in ten percent buffered formalin for histological studies.

Materials and Methods

The tissue was fixed in paraffin. The paraffin embedded tissue was sectioned to 3 to 4 μ thickness and stained with hematoxylin and eosin for histo-morphological studies (Bancroft and Stevens, 1996) ^[1]. By using ocular micrometer (Erma), each specimen was scanned at least 10 fields and the mean value for 5 observations was considered to be a measurable unit for each specimen during subsequent calculations. Intestinal villi length was measured and expressed in micro meter (μ m). The data collected was subjected to statistical analysis as per the method suggested by Snedecor and Cochran (1989) ^[3]. Angular transformation was applied to percentages wherever needed before carrying out statistical analysis.

Result and Discussion

Mean (\pm S. E.) intestinal villi length (μ m) of broilers reared in environmentally controlled housing system at five weeks of age as influenced by different levels of dietary sodium diformate is presented in the Table 1 and depicted in Plate1.

The analysis of variance of data revealed that supplementation of sodium diformate to broilers had significant influence on the intestinal villi length at five weeks of age.

Group T₆ recorded significantly ($P < 0.05$) higher intestinal villi length (2178.97 μm) followed by T₅ (1860.55 μm) and T₄ (1780.77 μm). The control group recorded the lowest intestinal villi length (1065.91 μm). The group T₂ also recorded significantly higher villi length (1611.57 μm) than the control group. Similarly Shih Hung *et al.* (2013) [2] also reported that supplementation of sodium diformate had increased the villus length in broilers.

Conclusion

It is concluded that feeding of sodium diformate had significantly ($P < 0.05$) increased the intestinal villi length in broilers. Broilers fed diet with 0.20 per cent (T₆) showed

significant increase ($P < 0.05$) in intestinal villi length compared to the control group.

Table 1: Mean (\pm S. E.) intestinal villi length (μm) of broilers reared in environmentally controlled housing system at five weeks of age as influenced by different levels of dietary sodium diformate

Treatment	Intestinal villi length (μm)
T ₁	1065.91 ^d \pm 49.92
T ₂	1611.57 ^c \pm 34.15
T ₃	1623.25 ^c \pm 38.19
T ₄	1780.77 ^b \pm 53.17
T ₅	1860.55 ^b \pm 41.41
T ₆	2178.97 ^a \pm 63.56

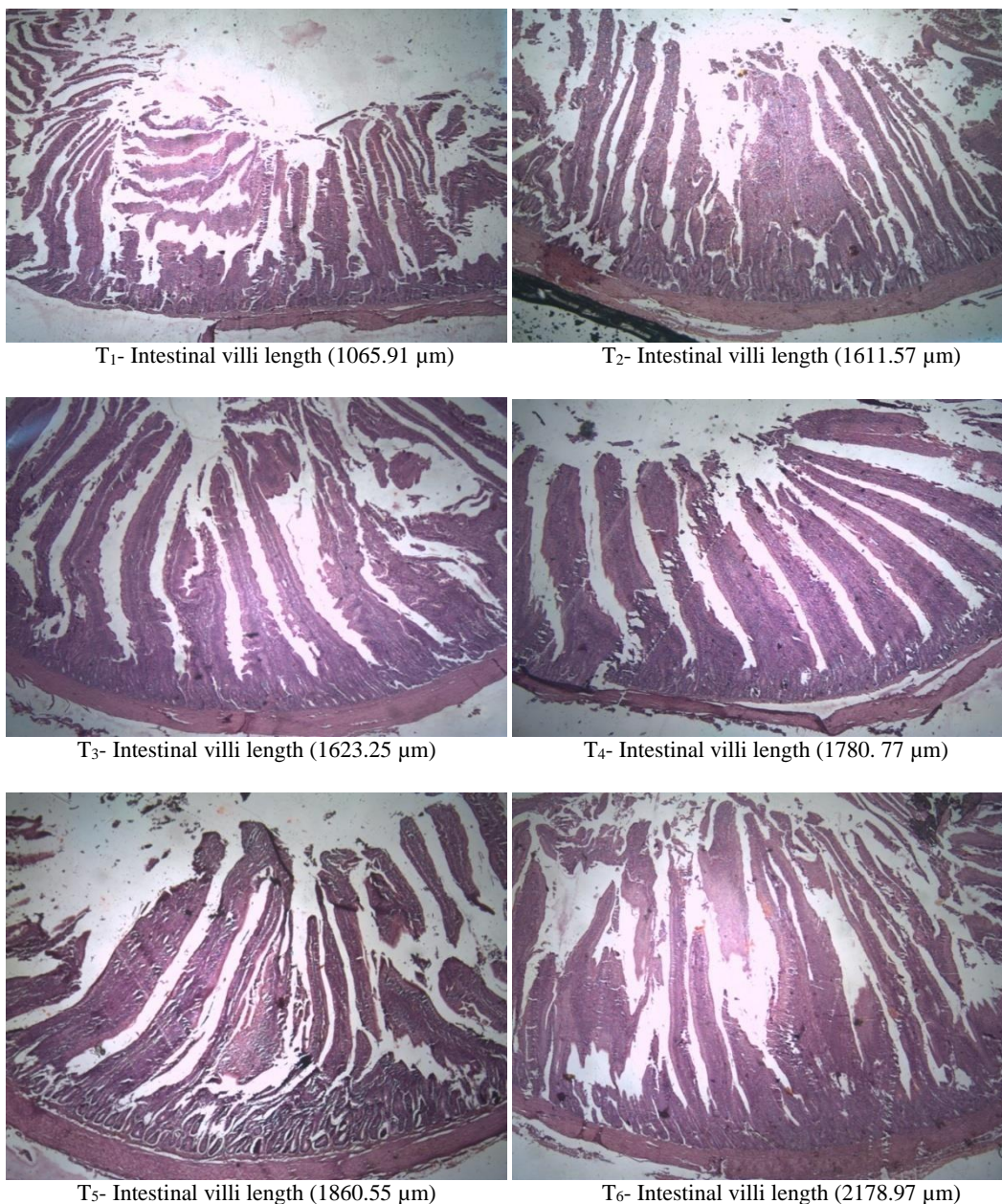


Plate 1: Mean intestinal villi length (μm) of broilers reared in environmentally controlled system at five weeks of age as influenced by different levels of dietary sodium diformate supplementation (H&E, x100)

References

1. Bancroft JD, Stevens A. Theory and practice of histological techniques. 4th edn, Churchill Livingstone, London, 1996.
2. ShihHung C, YaTing C, Fang Chun L, HowHong H. Effects of nutrient matrix value to sodium diformate on growth performances, intestinal microflora and gut mucosa morphology of broilers. J Chin. Soc. Ani. Sci. 2013; 42(3):205-216.
3. Snedecor GW, Cochran WG. Statistical Methods. 8th Edn, Iowa state university press, Ames, USA. Iowa – 50010, 1989.