



P-ISSN: 2349-8528
E-ISSN: 2321-4902
IJCS 2017; 5(2): 510-512
© 2017 JEZS
Received: 12-01-2017
Accepted: 13-02-2017

KB Dev Choudhury
Assistant Professor,
Department of Veterinary
Anatomy and Histology College
of Veterinary Science, AAU,
Khanapara, India

Munmun Sarma
Professor, Department of
Veterinary Anatomy and
Histology College of Veterinary
Science, AAU, Khanapara, India

M Talukdar
Professor, Department of
Veterinary Anatomy and
Histology College of Veterinary
Science, AAU, Khanapara, India

CK Gautam
Assistant Professor,
Department of Veterinary
Anatomy and Histology College
of Veterinary Science, AAU,
Khanapara, India

NN Barman
Professor, Department of
Veterinary, Microbiology, CVSc,
AAU, Department of Veterinary
Anatomy and Histology
College of Veterinary Science,
AAU, Khanapara, India

A Deka
Assistant Professor,
Department of Veterinary
Anatomy and Histology College
of Veterinary Science, AAU,
Khanapara, India

Correspondence

KB Dev Choudhury
Assistant Professor,
Department of Veterinary
Anatomy and Histology College
of Veterinary Science, AAU,
Khanapara, India

Anatomy of solitary lymphoid nodules in large intestine of post weaned pigs

KB Dev Choudhury, Munmun Sarma, M Talukdar, CK Gautam, NN Barman and A Deka

Abstract

Submucosal solitary lymphoid nodules of large intestine of pigs were scattered along the length and width of the colon and rectum and were mainly confined to the distal colon and rectum. Lymphoglandular complex (LGC) consisted of a well demarcated and partially encapsulated lymphocytic aggregate with variable numbers of lymphoid nodules with germinal centers in the rectum. In the colon, the LGCs typically consisted of a pore like depression on surface epithelium from which mucosal glands extended through a circular gap in the lamina muscularis mucosae and penetrated submucosal lymphoid tissue. The lymphoglandular complex resembled "Flask-shaped glands" Goblet cells were abundantly present in some crypt areas.

Keywords: Large intestine, lymphoid nodules, LGC, Pig

1. Introduction

In India, Animal Husbandry piggery sector directly influences the socio economic status of rural poor, more particularly the tribal population. It is a promising enterprise in entire North Eastern region of India because of low rearing cost, high prolificity, early marketable age and fast income generating potential. As the rural poor rear pigs under nomadic system, therefore, various diseases caused by different microbial agent has substantial health and economic impact.

The gut mucosa is effectively protected by a local organisation of lymphoid tissue. However, entry of antigen into the host is made possible by a special gateway comprising of "M" cells, located over organised lymphoid follicles. In large intestine, isolated lymphoid follicles give rise to solitary lymphoid nodules and lympho glandular complexes, which are responsible for sampling of gut antigen and production of local immunity. Large intestine requires higher level of mucosal protection as the large intestine is the site where food staff remains for a longer period and of ascending rectal infection.

The gut associated lymphoid tissue is formed by Peyer's patches in the small intestine and isolated or solitary lymphoid nodule in large intestine (Nickel *et.al.* 1996^[7] and Frappier, 2007)^[2].

To understand the antigen uptake by mucosa and a study of solitary lymphnode and lymphoglandular complex, it is necessary to know the anatomy of large intestine of pig. Keeping this fact in mind, the present study was undertaken to study gross anatomy and histological architecture of large intestine and solitary lymphoid nodules of pig.

2. Materials and Methods

The present study was conducted on 6(six) numbers of growing, apparently healthy piglets irrespective of sex and breed and after humane sacrifice the abdominal cavity was opened by laparotomy. Gross investigation on presence of solitary lymph node was done.

For Histological study, representative samples of 1 cm in size were collected from caecum, colon and rectum soon after the sacrifice of the piglets and preserved in 10% Neutral Buffered Formalin . Tissue samples were processed and embedded in paraffin wax as per the standard method of Luna (1968)^[6].

The paraffin blocks were cut at 5µm thickness and tissue sections were stained with standard histological and histochemical methods as per Luna (1968)^[6] as follows:

1. Routine Mayer's Haematoxylin and Eosin staining.
2. Van Gieson's method for collagen fibres.

3. Hart's method for elastic fibres.
4. Gomoris method for reticular fibres.

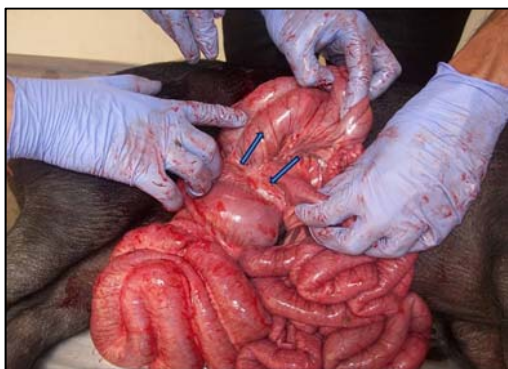

Fig 1: Photograph Showing Solitary Lymph Node (Arrow) In Large Intestine

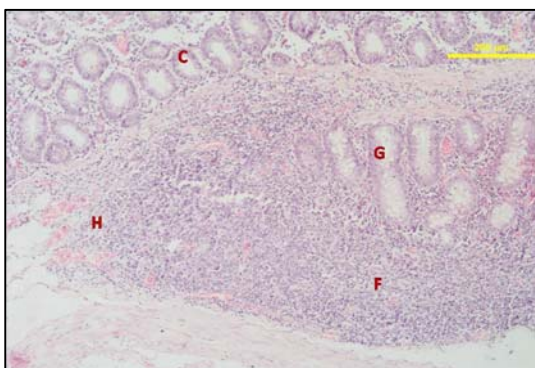


Fig 2: Photomicrograph Showing C-Crypt, F-Follicle, G-Gland, H-High Endothelial Venule. H&E X4

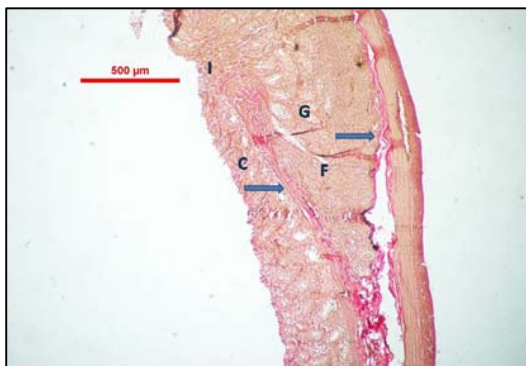


Fig 3: Photomicrograph Showing Collagen Fibres (Arrow) Of Lgc, C-Crypt, F-Follicle, G Gland, Hnvegination, Van Gieson X4

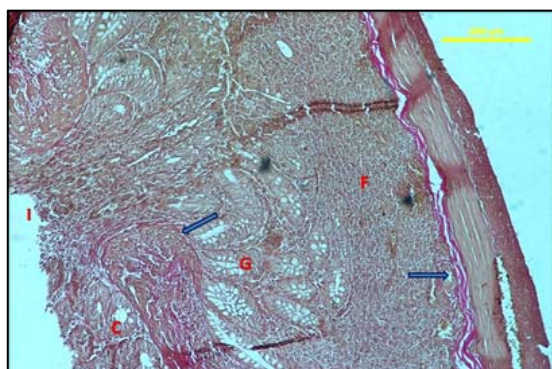


Fig 4: Photomicrograph Showing Collagen Fibres (Arrow) Of Lgc, C-Crypt, F-Follicle, G-Gland, Nvegination. Van Geson X10

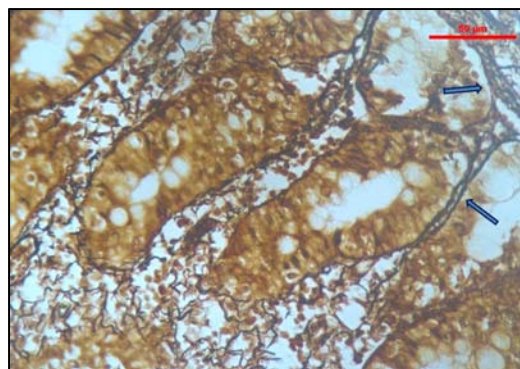


Fig 5: Photomicrograph Showing Reticular Fibres (Arrow) In Crypt of Caecum. Gomori's X10

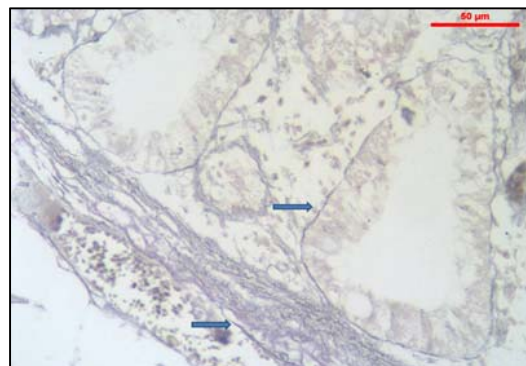


Fig 6: Photomicrograph Showing Elastic Fibres (Arrow) In Tunica Submucosa And Crypt Of Caecum. Hart's X10

3. Results and Discussions

In the present study submucosal solitary lymphoid nodules were present in the large intestine of pig and were scattered along the length and width of the colon and rectum in a experimental animals (Fig.1). However, in the proximal colon none was observed. The same was also reported by Gautam *et al.* (2013) [3] in goat. Peyer's patches was present in the ileo-caecal junction, the same was also reported by as reported by Talukdar , (1999) [8].

The lympho glandular complexes (LGCs) with lymphoid follicles were found in the tunica submucosa of distal caecum and rectum. The LGC consisted of a well demarcated and partially encapsulated lymphocytic aggregate (Fig.2). Variable numbers of lymphoid nodules with germinal centers were observed .The surface epithelial lining of LGC of large intestine showed invagination to the follicular complex (Fig.3). In the colon the LGCs typically consisted of a pore like depression on surface epithelium from which mucosal glands extended through a circular gap in the lamina muscularis mucosae and penetrated submucosal lymphoid tissue.This might be an access route of gut antigens to the lymphoglandular complex. The same was also observed by Gautam *et al.*, (2013) [3] in goat.

The lymphoglandular complex resembled the "Flask-shaped glands" (Fig.4) as depicted by Klein. According to his findings, these were "gland[s] of submucous tissue of colon surrounded by enlarged lymph-foilicle[s]" . LGCs in the descending colon were generally larger than the proximal colon. Goblet cells were abundantly present in some areas.

The follicles of LGCs were revealed presence of outer dark stained corona and inner light stained germinal centre . The outer cortical area of the follicles were covered by network of reticular fibers. The reticular fibers were also abundantly

present around the crypts (Fig.5) in the lamina propria. Similar findings were also reported by Gautam, C.K. (2015) [4].

In the present study, elastic fibres were present around the crypts and tunica sub mucosa(Fig. 6) but sparse at the periphery of the follicle. The collagen fibre bundles were present around the follicles (Fig. 3). The presence of collagen fibres in the pore like depression of tunica mucosa could not be traced, this might be for the passage of antigen to the LGCs.

4. References

1. Gautam CK, Talukdar M, Sarma K, Sarma S, Barman NN Baishya G. *et al.* Distribution and Histomorphology of Solitary Lymphoid Nodules of Large Intestine in Indigenous Goat of Assam (*Capra hircus*). Indian Vet. J. 2013; 90(8):18-20.
2. Frappier BL. Dellmann's Text book of histology. 6th Edition. Blackwell Publishing, Asia. 2007; 194-201.
3. Gautam CK. Anatomical studies on gut associated lymphoid tissue (GALT) in indigenous adult goat of Assam(*Capra hircus*), M.V.Sc. Thesis submitted to Assam Agricultural University, Jorhat. 2013.
4. Gautam CK. Antigen uptake and comparative histomorphology and ultrastructure of the histocompartments of Peyer's patches and solitary lymphoid nodules of intestine of growing piglet Ph.D. Thesis submitted to Assam Agricultural University, Jorhat. 2015.
5. Klein E. Report on infectious pneumo-enteritis of the pig (so-called pig-typhoid). Seventh annual report of the local government board 1877-78. Supplement containing the report of the medical officer for. 1878; 169-280.
6. Luna LG. Manuals of Histologic Staining Method of Armed Forces Institute of Pathology. 3rd Ed. Mc. Graw Hill Book Company, New York. 1968.
7. Nickel R, Schmmur A, Seiferle E. The viscera of domestic mammals. 2nd Edition. Verlag Paul Parey. Berlin. Hamburg Blackwell Publishing. 1996; 101-194.
8. Talukdar M. Ph.D. Thesis submitted to the Assam Agricultural University, Assam, India. 1999.