International Journal of Chemical Studies

P-ISSN: 2349–8528
E-ISSN: 2321–4902
IJCS 2019; 7(3): 3677-3678

Received: 28-03-2019
Accepted: 30-04-2019

Venkatesakumar E
Assistant Professor, Department of Veterinary Clinical Medicine, Veterinary College and Research Institute, Namakkal, TANUVAS, Tamil Nadu, India

Ramprabhu R
Professor and Head, Veterinary Clinical Complex, Veterinary College and Research Institute, Tirunelveli, TANUVAS, Tamil Nadu, India

Kumar V
Assistant Professor, Department of Veterinary Pathology, Veterinary College and Research Institute, Tirunelveli, TANUVAS, Tamil Nadu, India

Enbavelan PA
Assistant Professor, Department of Veterinary Medicine, Veterinary College and Research Institute, Tirunelveli, TANUVAS, Tamil Nadu, India

Correspondence
Venkatesakumar E
Assistant Professor, Department of Veterinary Clinical Medicine, Veterinary College and Research Institute, Namakkal, TANUVAS, Tamil Nadu, India

Diagnosis and management of concurrent infection of Ehrlichiosis and Dirofilariasis in a miniature pinscher dog

Venkatesakumar E, Ramprabhu R, Kumar V and Enbavelan PA

Abstract
A three year old male Miniature Pinscher dog was reported with the history of anorexia, vomiting, intermittent fever and coughing for one week. Icteric mucous membrane, pyrexia (40.2º C), enlarged superficial lymph nodes and ecchymotic patches on the ventral abdomen were noticed. Ticks were present on the animal. Peripheral blood smear examination revealed morula of *Ehrlichia canis* in monocytes and Dirofilaria organism. Haematological examination showed anaemia, thrombocytopenia and monocytosis. Elevated blood urea nitrogen and serum creatinine were observed. Radiography revealed cardiomegaly. Abdominal ultrasound examination revealed indistinct cortico-medullary junction in both kidneys. The dog was treated with Ringer's lactate, Dextrose normal saline, ivermectin, Doxycycline, pantoprazole, diethylcarbamazine and prednisolone. The animal showed clinical improvement after the treatment.

Keywords: Ehrlichiosis, Dirofilariasis, Doxycycline, Diethycabamazine, Thrombocytopenia

Introduction
Haemoprotozoan diseases in dogs are more common in tropical and subtropical regions (Irwin and Jefferies, 2004) [3]. Concurrent infections of Ehrlichia, Babesia, Anaplasma, Hepatozoan and heart worm have been reported in dogs (O'Dwyer *et al*., 2001) [9]. The major vector tick, *Rhipicephalus sanguineus* is widespread in tropics and transmits *Ehrlichia canis.* Canine Monocytic Ehrlichiosis (CME) is caused by *E. canis* which is an obligate intracellular parasite often infects the white blood cells of mammals especially monocytes. Dirofilariasis in dogs is caused by filarial nematode *Dirofilaria immitis*. It is mainly transmitted by mosquito vector. The present study report the clinical signs, diagnosis and therapeutic management of concurrent infection of *E. canis* and *Dirofilaria immitis* in a Miniature pinscher dog.

Case History and Clinical Observations
A male Miniature Pinscher dog aged about 3 years was reported to Small Animal Medical section of Veterinary Clinical Complex, Veterinary College and Research Institute, Tirunelveli with the history of anorexia, vomiting, intermittent fever and coughing for the past one week. The animal was dull and depressed. Clinical examination revealed icteric mucous membrane (Fig. 1), pyrexia (40.2º C), enlarged superficial lymph nodes and ecchymotic patches on the ventral abdomen (Fig. 2). Ticks were present on the animal. Peripheral blood smear examination revealed morula of *Ehrlichia canis* in monocytes and Dirofilaria organism (Fig. 3). *Dirofileria immitis* was identified using Modified knott's technique. Haematological examination showed decreased haemoglobin (8 g%), packed cell volume (22 %), red blood cells (2.8 x10^6/cumm), platelet count (54,000/cumm) and monocytosis (8 %). Elevated blood urea nitrogen (116 mg/dl) and serum creatinine (2.8 mg/dl) were observed. Radiography revealed right side cardiac enlargement. Abdominal ultrasound examination revealed indistinct cortico-medullary junction in both kidneys.

Treatment and Discussion
The animal was treated with Ringer's lactate (@ 5 ml/kg i/v), Dextrose normal saline (@ 5ml/kg i/v) for five days, Ivermectin (@ 0.2 mg/kg s/c twice at 15 days interval), Doxycycline (@ 10mg/kg PO daily for 28 days), Pantoprazole (@ 1 mg/kg PO daily for 28 days before food), Diethylcarbamazine (@ 6 mg/kg PO daily for 60 days), Prednisolone (@ 0.5 mg/kg PO

daily for seven days) and oral haematinics (aRBC pet liquid). The animal showed improvement 5 days after the initiation therapy.

Sharma *et al*. (2015) reported anaemia in the concurrent infection of ehrlichiosis, anaplasmosis and Dirofilariasis in dogs. In the present study, anaemia might be due to decreased RBC production, excessive consumption and/or destruction of blood cellular component, decreased RBC survival and lack of erythropoitic response in Ehrlichiosis as suggested by Harrus and Waner (2013) [7] and also due to Dirofilariasis (Rath *et al*., 2014) [4]. Thrombocytopenia observed in the present study is in accordance with Harrus *et al*. (1997) [6] who described that the thrombocytopenia in Ehrlichiosis infection in dogs could be due to increased platelet consumption in blood vessel endothelium, increased spleenic sequestration of platelets and immunological destruction or injury with decreased platelet life span. In the present study, ecchymotic patches were mainly due to thrombocytopenia resulting from platelet bound auto antibodies in chronic ehrlichiosis (Neer *et al*., 2002) [2]. Elevated BUN and creatinine were seen in neutrophilic Ehrlichiosis in a dog (Chandrasekaran *et al.*, 2016) [1] and also in Dirofilariasis due to cardiac and renal involvement (Niwetpathomwa *et al*., 2007) [8]. Right sided heart failure and pulmonary thromboembolism were observed in Dirofilariasis infection of dogs (Nelson, 2012) [2]. Treatment with Doxycycline, ivermectin and diethylcarbamazine were effective in the management of concurrent infection of Ehrlichiosis and Dirofilariasis in dogs.

Fig 1: Icteric mucous membrane

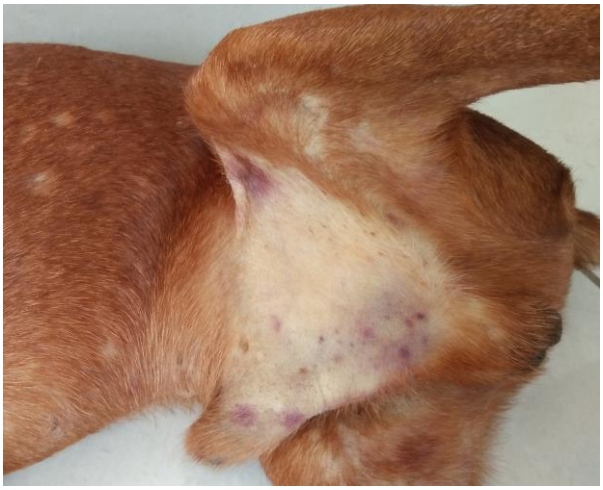

Fig 2: Ecchymotic patches in the ventral abdomen

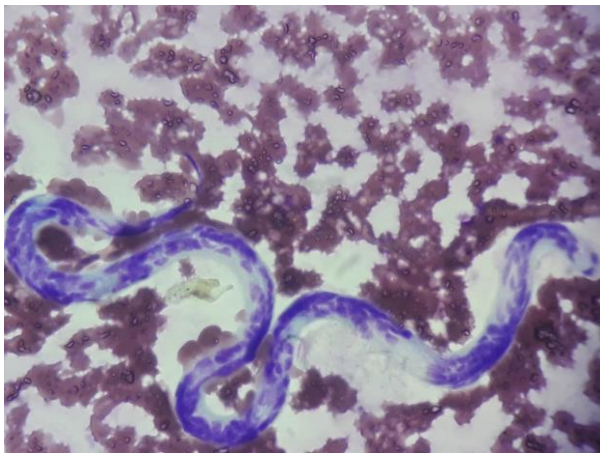

Fig 3: *Dirofilaria immitis* in blood smear (LG stain)

Acknowledgement

The authors are thankful to the Dean, Veterinary College and Research Institute, Tirunelveli, TANUVAS, Tamilnadu for the facilities provided for the study.

References

1. Chandrasekaran D, Senthil NR, Kavitha S, Subapriya S, Jeyaraja K, Vairamuthu S. Neutrophilic Ehrlichiosis in a dog – A case report. Indian Vet J. 2016; 93(8):53-54.
2. Neer TM, Breitschwerdt EB, Greene RT, Lappin MR. Consensus statement on ehrlichial disease of small animals from the infectious disease study group of the ACVIM. J Vet. Intern. Med. 2002; 16:309-315.
3. Irwin PJ, Jafferies R. Arthropod-transmitted diseases of companion animals in Southeast Asia. Trends Parasitol. 2004; 20:27-34.
4. Rath PK, Panda SK, Mishra BP, Patra RC, Nath I, Sahoo G. Haematobiochemical observations in naturally affected Dirofilariasis in dogs in Odisha. Indian Vet J. 2014; 91(8):49-52.
5. Nelson CT. Heart worm disease: In Infectious diseases of the dog and cat, edited by Greene. C.E. 4th ed, Elsevier publication, USA. 2012, 865-877.
6. Harrus S, Aroch I, Lavy E. Clinical manifestations of infectious canine cyclic thrombocytopenia Vet. Rec. 1997, 141:247.
7. Harrus S, Waner T. Canine monocytic Ehrilichiosis-from pathology to clinical manifestation. Israel J Vet Med. 2013; 68:292-296.
8. Niwetpathomwat A, Kaewthamasorn M, Tiawsirisup S, Techangamsuwan S, Suvarnvibhaja S. A retrospective study of the clinical haematology and the serum biochemical tests made on canine Dirofilariasis cases in an animal hospital population in Bangkok, Thailand. Res. Vet. Sc. 2007; 82(3):364-369.
9. O'Dwyer LH, Massard CL, Pereira De Souza JC. *Hepatozoon canis* infection associated with dog ticks of rural areas of Rio de Janeiro State, Brasil. Vet. Parasitol. 2001; 94:143-150.